CLINICA
PUBLICATION

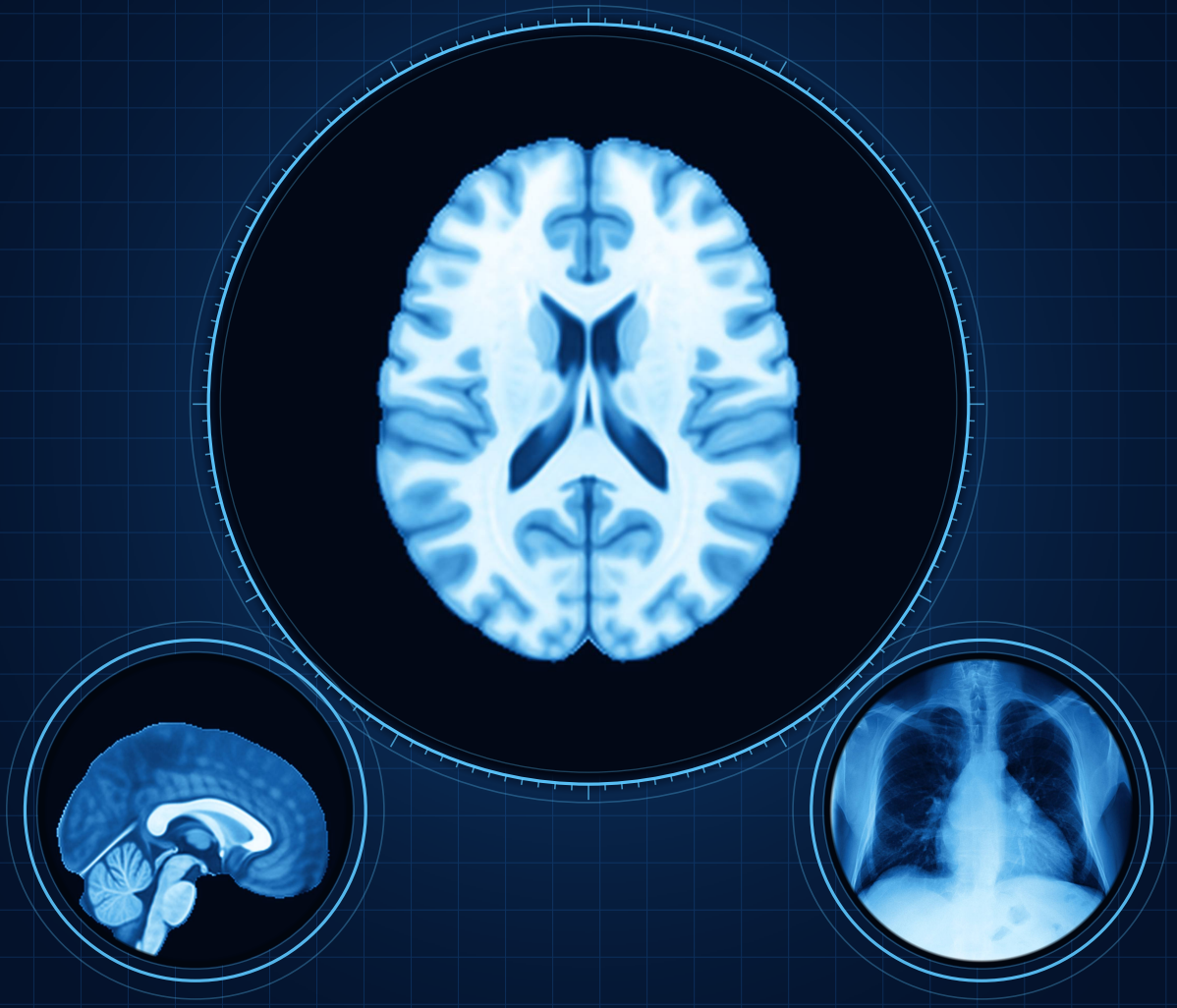

DNB Radiodiagnosis

Solved Previous-Year Questions

SAMPLE

REVIEWED BY

Dr Hemant Kumar · Dr. Khusbo Singh

DNB Radiodiagnosis

UPDATED TILL OCTOBER 2026

Visit www.clinicapublication.com to order

THE SERIES

Four Volumes, One Exam

The DNB Radiodiagnosis Exit Exam series covers the complete theory syllabus in four volumes and 347 solved answers. Part numbers run continuously across the series.

VOLUME I

Physics & Techniques · Breast · Vascular & Interventional

100 answers

Part 1 · X-ray physics, equipment and radiography
Part 2 · Computed tomography — technology and do…
Part 3 · Ultrasound physics, Doppler and elastography
Part 4 · MRI physics and advanced MR techniques
Part 5 · Contrast media
Part 6 · Radiation protection, dosimetry and regulation
Part 7 · Nuclear medicine and molecular imaging
Part 8 · Research, informatics, AI and recent advances
Part 9 · Breast imaging
Part 10 · Vascular imaging and Doppler
Part 11 · Interventional radiology — techniques and de…

VOLUME II

Chest · Cardiac · Gastrointestinal Tract

81 answers

Part 12 · Chest — lungs, airways, pleura, mediastinum and diaphragm
Part 13 · Cardiac and coronary imaging
Part 14 · Gastrointestinal tract, peritoneum, mesentery and retroperitoneum

VOLUME III

Trauma · Hepatobiliary · Genitourinary · Obs & Gynae

77 answers

Part 15 · Body trauma
Part 16 · Liver, biliary system and pancreas
Part 17 · Genitourinary, adrenal and male reproductive
Part 18 · Obstetrics and fetal imaging
Part 19 · Gynaecology and the female pelvis

VOLUME IV

Neuro · Spine · Head & Neck · Musculoskeletal

89 answers

Part 20 · Neuroradiology — brain
Part 21 · Spine and spinal cord
Part 22 · Head and neck
Part 23 · Musculoskeletal radiology

Reviewers

Dr Hemant Kumar
DNB Radiodiagnosis

Dr. Khusbo Singh
DNB Radiodiagnosis

Published by Clinica Publication · www.clinicapublication.com
© 2026 Clinica Publication. All rights reserved. No part of this book may be reproduced, stored or transmitted in any form without the prior written permission of the publisher.

Disclaimer. This book is an exam-preparation aid written from the standard textbooks and guidelines named in each answer. Radiology practice, classifications and regulations change; readers should confirm doses, protocols and recommendations against current official sources before applying them to patient care. Textbook figures are reproduced with their source and page for study reference.

CLINICA
PUBLICATION

DNB EXIT EXAM · SOLVED PREVIOUS-YEAR QUESTION PAPERS

DNB Radiodiagnosis

Solved Previous-Year Questions

VOLUME I

Physics, Techniques, Contrast, Radiation Safety, Nuclear Medicine, Research; Breast, Vascular and Interventional

Answers are written from six radiology textbooks — Grainger & Allison 7e, Rumack & Levine 6e, Chapman & Nakielny 7e, Christensen 4e, AIIMS-MAMC-PGI 3e and Core Radiology 2e — one lead book per question, with the chapter and pages named in each answer, and from current reporting systems, guidelines and Indian regulations found on official sites, listed in the Web-Sourced Facts Register.

REVIEWED BY

Dr Hemant Kumar
DNB Radiodiagnosis

Dr. Khusbo Singh
DNB Radiodiagnosis

UPDATED TILL OCTOBER 2026

CLINICA PUBLICATION
www.clinicapublication.com

Index

HOW TO USE

Each answer groups every year and paper the question was asked in and is written to the union of what those versions asked. The badge shows how often it was asked. The SOURCE box under each question names the textbook chapters and pages used and any current guideline or web source [W#]; every [W#] is also listed in the register at the end. Book images carry their own figure number and page; anatomy and diagram questions also carry a schematic exam diagram you can reproduce in 2–3 minutes. A lists the parts, B this volume question by question, C the high-yield topics (asked 3× or more).

A · Parts

Part 1 — X-ray physics, equipment and radiography	12 answers	10
Part 2 — Computed tomography — technology and dose	7 answers	45
Part 3 — Ultrasound physics, Doppler and elastography	7 answers	68
Part 4 — MRI physics and advanced MR techniques	17 answers	93
Part 5 — Contrast media	7 answers	149
Part 6 — Radiation protection, dosimetry and regulation	7 answers	176
Part 7 — Nuclear medicine and molecular imaging	6 answers	191
Part 8 — Research, informatics, AI and recent advances	10 answers	211
Part 9 — Breast imaging	8 answers	240
Part 10 — Vascular imaging and Doppler	12 answers	266
Part 11 — Interventional radiology — techniques and devices	7 answers	315

B · This volume, question by question

1. X-ray tube — construction, X-ray production and tube failure Asked in: Dec 2021 · Paper IV · Q1 (10 marks) · Dec 2022 · Paper IV · Q9 (10 marks) · Apr 2023 · Paper IV · Q10(b) (5 marks) · Jun 2025 · Paper IV · Q10(a) (5 marks)	4×	10
2. Rotating anode X-ray tube and its advantages Asked in: Jun 2020 · Paper IV · Q1(a) (5 marks) · Dec 2020 · Paper IV · Q4(a) (5 marks)	2×	14
3. Photoelectric effect Asked in: Dec 2020 · Paper IV · Q4(b) (5 marks)	1×	16
4. X-ray beam-restricting devices — types and uses Asked in: Jun 2020 · Paper IV · Q1(b) (5 marks) · Apr 2023 · Paper IV · Q10(a) (5 marks)	2×	18
5. Scatter radiation and radiographic grids — structure, types, grid ratio, advantages and disadvantages Asked in: Jun 2021 · Paper IV · Q4 (10 marks) · Jun 2022 · Paper IV · Q2 (10 marks)	2×	21
6. Rare-earth intensifying screens Asked in: Dec 2020 · Paper IV · Q6(a) (5 marks)	1×	26
7. X-ray film — structure and characteristics Asked in: Dec 2021 · Paper IV · Q2(a) (5 marks)	1×	28
8. Computed radiography and digital radiography — principles, advantages and disadvantages Asked in: Jun 2020 · Paper IV · Q3 (10 marks) · Dec 2021 · Paper IV · Q2(b) (5 marks) · Dec 2025 · Paper IV · Q2(b) (5 marks)	3×	30
9. Handheld digital radiography system Asked in: Apr 2023 · Paper IV · Q5(a) (5 marks)	1×	34
10. Flat-panel detectors — composition and image formation in direct and indirect types Asked in: Oct 2024 · Paper IV · Q10 (10 marks)	1×	36
11. Image intensifier — construction, properties and limitations Asked in: Dec 2020 · Paper IV · Q8 (10 marks)	1×	40
12. Pulsed fluoroscopy Asked in: Jun 2022 · Paper IV · Q4(a) (5 marks)	1×	43

13. Dual-energy CT — principle, acquisition methods and applications including pulmonary Asked in: Jun 2020 · Paper IV · Q5(a) (5 marks) · Dec 2020 · Paper IV · Q1 (10 marks) · Dec 2022 · Paper IV · Q2 (10 marks) · Jun 2025 · Paper IV · Q7 (10 marks)	4×	45
14. CT dose — CTDIvol, DLP and dose reduction in CT and radiography Asked in: Dec 2022 · Paper IV · Q4 (10 marks) · Apr 2023 · Paper IV · Q7 (10 marks) · Dec 2025 · Paper IV · Q3 (10 marks)	3×	50
15. Low-dose and ultra-low-dose CT of the chest — technique and role Asked in: Oct 2024 · Paper II · Q8 (10 marks)	1×	55
16. CT artefacts Asked in: May 2024 · Paper IV · Q5 (10 marks)	1×	59
17. Cone-beam CT Asked in: Jun 2021 · Paper IV · Q9(a) (5 marks)	1×	62
18. Mobile CT scanner and its applications Asked in: Apr 2023 · Paper IV · Q5(b) (5 marks)	1×	65
19. Photon-counting CT Asked in: Dec 2025 · Paper IV · Q9(a) (5 marks)	1×	66
20. Ultrasound artefacts — causes, reduction and clinical utility Asked in: Jun 2020 · Paper IV · Q5(b) (5 marks) · Dec 2022 · Paper IV · Q10 (10 marks)	2×	68
21. Tissue harmonic imaging Asked in: Dec 2020 · Paper IV · Q9(a) (5 marks)	1×	73
22. Colour Doppler — principle, Nyquist limit and artefacts and their prevention Asked in: Dec 2021 · Paper IV · Q9(a) (5 marks) · Jun 2022 · Paper II · Q6 (10 marks) · May 2024 · Paper II · Q9 (10 marks)	3×	76
23. Ultrasound elastography — principles, techniques and applications including diffuse liver disease Asked in: Jun 2021 · Paper IV · Q2 (10 marks) · Jun 2022 · Paper IV · Q1 (10 marks) · Oct 2023 · Paper IV · Q5 (10 marks)	3×	81
24. Sonoelastography in obstetrics and gynaecology Asked in: Apr 2023 · Paper IV · Q4(a) (5 marks)	1×	85
25. Ultrasound elastography of breast lesions Asked in: May 2024 · Paper IV · Q2 (10 marks)	1×	87
26. MR elastography — principle and abdominal applications Asked in: Jun 2025 · Paper IV · Q5 (10 marks)	1×	90
27. Parallel imaging in MRI — principle and technique Asked in: Jun 2022 · Paper IV · Q3 (10 marks)	1×	93
28. K-space and its use in MR sequences Asked in: Jun 2022 · Paper IV · Q8 (10 marks)	1×	96
29. Chemical shift imaging in MRI — advantages and disadvantages Asked in: Jun 2022 · Paper IV · Q7 (10 marks)	1×	100
30. Fat suppression techniques in MRI Asked in: Jun 2022 · Paper IV · Q9 (10 marks)	1×	104
31. MRI artefacts, including motion artefacts and their reduction Asked in: Dec 2020 · Paper IV · Q9(b) (5 marks) · Jun 2021 · Paper IV · Q7 (10 marks) · Jun 2025 · Paper IV · Q4(b) (6 marks)	3×	106
32. MRI radiofrequency coils Asked in: Jun 2025 · Paper IV · Q4(a) (4 marks)	1×	110
33. 3 T versus 1.5 T MRI — advantages and limitations Asked in: Apr 2023 · Paper IV · Q3(a) (6 marks) · Dec 2025 · Paper IV · Q2(a) (5 marks)	2×	113
34. MRI safety — hazards, zoning of the MRI facility and safety considerations Asked in: Jun 2021 · Paper IV · Q9(b) (5 marks) · Apr 2023 · Paper IV · Q3(b) (4 marks) · Dec 2025 · Paper IV · Q6 (10 marks)	3×	115
35. Diffusion-weighted imaging — principle, restricted diffusion in the brain and non-neurological uses Asked in: Jun 2021 · Paper IV · Q1 (10 marks) · Dec 2021 · Paper IV · Q10(b) (5 marks)	2×	120
36. MR perfusion — techniques and role in brain tumours Asked in: Jun 2022 · Paper IV · Q6 (10 marks) · Dec 2025 · Paper IV · Q4(a) (5 marks)	2×	124

37. MR spectroscopy of the brain — principles, techniques and role in brain pathologies and ring-enhancing lesions Asked in: Jun 2020 · Paper I · Q9 (10 marks) · Oct 2024 · Paper IV · Q1 (10 marks)	2×	127
38. MR angiography — time-of-flight and phase-contrast principles, applications and pitfalls Asked in: Jun 2020 · Paper IV · Q4 (10 marks) · Dec 2021 · Paper IV · Q9(b) (5 marks) · Dec 2022 · Paper IV · Q3 (10 marks)	3×	131
39. Susceptibility-weighted imaging of the brain — principle and clinical utility Asked in: Dec 2022 · Paper IV · Q1 (10 marks)	1×	136
40. BOLD imaging — basis, utility and limitations Asked in: Oct 2023 · Paper IV · Q4 (10 marks)	1×	141
41. MR neurography and black-blood imaging of the brain Asked in: Apr 2023 · Paper IV · Q1 (10 marks)	1×	143
42. CSF flow imaging — technique and indications Asked in: Oct 2024 · Paper IV · Q9 (10 marks)	1×	145
43. Zero-TE MRI and its applications Asked in: Dec 2025 · Paper IV · Q5(b) (5 marks)	1×	148
44. Iodinated contrast media — classification, adverse reactions and management including emergency drugs and anaphylaxis Asked in: Jun 2020 · Paper IV · Q2 (10 marks) · Dec 2020 · Paper IV · Q5 (10 marks) · Dec 2021 · Paper IV · Q8(b) (5 marks) · Oct 2023 · Paper IV · Q8 (10 marks)	4×	149
45. Non-ionic water-soluble contrast agents and their superiority over ionic agents Asked in: May 2024 · Paper IV · Q6 (10 marks)	1×	153
46. Contrast-induced nephropathy — definition, pathogenesis and prevention Asked in: Jun 2025 · Paper IV · Q3 (10 marks)	1×	156
47. Hepatobiliary-specific MR contrast agents and their role in focal liver lesions Asked in: Jun 2021 · Paper III · Q3 (10 marks) · Apr 2023 · Paper IV · Q9(a) (5 marks)	2×	161
48. MRI contrast media and nephrogenic systemic fibrosis — risk factors and risk reduction Asked in: Jun 2021 · Paper IV · Q8 (10 marks) · Dec 2025 · Paper IV · Q7(a) (5 marks)	2×	165
49. Ultrasound contrast agents — composition, generations, mechanism, applications, advantages and limitations Asked in: Jun 2021 · Paper IV · Q5 (10 marks) · Dec 2021 · Paper IV · Q3(a) (5 marks) · Oct 2024 · Paper IV · Q5 (10 marks)	3×	169
50. Enteric (oral) contrast and bowel preparation for CT Asked in: Dec 2021 · Paper IV · Q3(b) (5 marks) · Dec 2025 · Paper IV · Q7(b) (5 marks)	2×	173
51. Radiation protection — cardinal principles and protection of staff, patients and public Asked in: Dec 2021 · Paper IV · Q7 (10 marks) · May 2024 · Paper IV · Q7(b) (5 marks) · Jun 2025 · Paper IV · Q10(b) (5 marks)	3×	176
52. ALARA and eLORA Asked in: Dec 2021 · Paper IV · Q5(a) (5 marks)	1×	180
53. Zero-lead (lead-free) aprons Asked in: Jun 2022 · Paper IV · Q4(b) (5 marks)	1×	181
54. Quality assurance in diagnostic radiology — meaning and aims Asked in: May 2024 · Paper IV · Q7(a) (5 marks)	1×	183
55. Biological effects of radiation, maximum permissible dose and AERB dose limits Asked in: Jun 2021 · Paper IV · Q3 (10 marks) · Oct 2024 · Paper IV · Q6 (10 marks)	2×	185
56. Thermoluminescent dosimeter (TLD) badge — principles and uses Asked in: Jun 2020 · Paper IV · Q9(b) (5 marks) · Dec 2020 · Paper IV · Q6(b) (5 marks) · Dec 2025 · Paper IV · Q10(b) (5 marks)	3×	188
57. PC-PNDT Act and its applications Asked in: Jun 2020 · Paper IV · Q9(a) (5 marks) · Dec 2025 · Paper IV · Q10(a) (5 marks)	2×	190
58. PET-MRI Asked in: Jun 2020 · Paper IV · Q10(b) (5 marks)	1×	191

59. PET scanning — principle, FDG-PET in oncology and non-FDG tracers Asked in: Dec 2021 · Paper IV · Q8(a) (5 marks) · Oct 2023 · Paper IV · Q9 (10 marks)	2×	193
60. Cardiac scintigraphy — myocardial perfusion and viability Asked in: Dec 2021 · Paper IV · Q10(a) (5 marks) · Oct 2023 · Paper IV · Q3 (10 marks)	2×	198
61. Radionuclide studies of the urinary tract and renal infection Asked in: Dec 2022 · Paper IV · Q8 (10 marks) · Jun 2025 · Paper IV · Q2(b) (5 marks)	2×	201
62. Isotopes in the evaluation of thyroid lesions Asked in: Apr 2023 · Paper IV · Q2 (10 marks)	1×	206
63. HIDA scan Asked in: Dec 2025 · Paper IV · Q1(b) (5 marks)	1×	209
64. Randomisation techniques and the randomised controlled trial Asked in: Jun 2020 · Paper IV · Q8(b) (5 marks) · Dec 2025 · Paper IV · Q8(a) (5 marks)	2×	211
65. Types of study design in research Asked in: Dec 2022 · Paper IV · Q7(b) (8 marks) · Oct 2024 · Paper IV · Q3 (10 marks)	2×	213
66. Sampling methods in research Asked in: May 2024 · Paper IV · Q3 (10 marks)	1×	215
67. Accuracy, positive and negative predictive value — definitions and clinical usefulness Asked in: Oct 2023 · Paper IV · Q10 (10 marks)	1×	217
68. Plagiarism in scientific writing — types, detection and prevention Asked in: Jun 2020 · Paper IV · Q7 (10 marks)	1×	221
69. Predatory journals and the journal impact factor Asked in: Jun 2020 · Paper IV · Q8(a) (5 marks) · Dec 2022 · Paper IV · Q7(a) (2 marks)	2×	224
70. Artificial intelligence in radiology Asked in: Jun 2020 · Paper IV · Q10(a) (5 marks) · Jun 2022 · Paper IV · Q10(b) (5 marks) · Jun 2025 · Paper IV · Q9 (10 marks)	3×	226
71. PACS, RIS and teleradiology Asked in: May 2024 · Paper IV · Q8 (10 marks) · Oct 2024 · Paper IV · Q8(a) (5 marks)	2×	230
72. Post-mortem imaging and post-mortem CT — applications Asked in: Apr 2023 · Paper IV · Q8 (10 marks) · Jun 2025 · Paper IV · Q6(b) (5 marks)	2×	234
73. Non-invasive imaging of the central lymphatics — recent techniques Asked in: Dec 2020 · Paper IV · Q10 (10 marks)	1×	237
74. Breast MRI — indications, technique, advantages, limitations, non-mass enhancement and benign vs malignant Asked in: Jun 2020 · Paper I · Q4 (10 marks) · Dec 2020 · Paper I · Q4 (10 marks) · Jun 2021 · Paper I · Q7 (10 marks) · Oct 2024 · Paper I · Q4 (10 marks)	4×	240
75. Palpable breast mass — differential diagnosis, ultrasound role and benign vs malignant on US and MRI Asked in: Dec 2021 · Paper I · Q4 (10 marks) · Apr 2023 · Paper I · Q5(b) (5 marks)	2×	244
76. BI-RADS classification system Asked in: Apr 2023 · Paper I · Q5(a) (5 marks)	1×	249
77. Digital breast tomosynthesis — principle and advantages Asked in: Jun 2022 · Paper IV · Q10(a) (5 marks) · Dec 2025 · Paper I · Q5 (first part) (5 marks)	2×	251
78. Suspicious calcifications on mammography Asked in: Dec 2025 · Paper I · Q5 (second part) (5 marks)	1×	254
79. Contrast-enhanced mammography Asked in: Oct 2024 · Paper IV · Q8(b) (5 marks)	1×	257
80. Mammography X-ray tube Asked in: Dec 2025 · Paper IV · Q9(b) (5 marks)	1×	259
81. Axillary swelling — imaging approach and differential diagnosis Asked in: May 2024 · Paper I · Q5 (10 marks)	1×	261

82. Acute aortic syndrome and aortic dissection — classification, CT angiography and management Asked in: Jun 2020 · Paper II · Q4 (10 marks) · Dec 2020 · Paper II · Q5 (10 marks) · Jun 2025 · Paper II · Q3(b) (5 marks)	3×	266
83. Aortic aneurysm — causes, CT angiography features and endovascular repair Asked in: Oct 2023 · Paper II · Q4 (10 marks)	1×	274
84. Lower-limb arterial (and venous) anatomy with labelled diagrams Asked in: Dec 2020 · Paper II · Q4(a) (5 marks) · Jun 2025 · Paper II · Q9(a) (5 marks)	2×	279
85. Acute limb ischaemia — imaging approach, Doppler and interventional treatment Asked in: Jun 2020 · Paper II · Q9 (10 marks) · Apr 2023 · Paper II · Q3(a) (5 marks)	2×	282
86. Peripheral arterial disease — imaging modalities, CTA and MRA technique, and Doppler findings Asked in: Jun 2021 · Paper II · Q6 (10 marks) · Oct 2024 · Paper II · Q5 (10 marks) · Jun 2025 · Paper II · Q9(b) (5 marks)	3×	286
87. Carotid arterial anatomy and the role of colour Doppler, including in TIA Asked in: Oct 2023 · Paper II · Q9 (10 marks) · Dec 2025 · Paper II · Q8(b) (5 marks)	2×	290
88. Renal artery stenosis — US, Doppler, MR angiography and intervention Asked in: Dec 2020 · Paper III · Q8 (10 marks) · Dec 2021 · Paper II · Q10(b) (5 marks) · Dec 2022 · Paper II · Q6 (10 marks)	3×	295
89. Deep venous thrombosis — imaging Asked in: Dec 2020 · Paper II · Q4(b) (5 marks)	1×	298
90. Varicose veins and venous incompetence — Doppler and interventional treatment Asked in: Dec 2021 · Paper II · Q8(a) (5 marks) · Dec 2022 · Paper II · Q7 (10 marks) · Dec 2025 · Paper II · Q8(a) (5 marks)	3×	301
91. Vascular anomalies — ISSVA classification Asked in: Jun 2022 · Paper II · Q1 (10 marks)	1×	305
92. Peripheral vascular malformations — diagnostic approach, Doppler and MRI, and interventional management Asked in: Oct 2023 · Paper II · Q2 (10 marks) · May 2024 · Paper II · Q8 (10 marks) · Oct 2024 · Paper II · Q7 (10 marks)	3×	308
93. Doppler evaluation of the dialysis arteriovenous fistula Asked in: Apr 2023 · Paper II · Q9(b) (5 marks)	1×	312
94. Embolic agents — classification, advantages, disadvantages and clinical applications Asked in: Jun 2020 · Paper IV · Q6 (10 marks) · Dec 2020 · Paper IV · Q3 (10 marks) · Dec 2022 · Paper IV · Q6 (10 marks) · Jun 2025 · Paper IV · Q8 (10 marks)	4×	315
95. Radiofrequency ablation — principle, indications, contraindications, complications and applications Asked in: Jun 2021 · Paper IV · Q6 (10 marks) · Oct 2023 · Paper IV · Q7 (10 marks) · Dec 2025 · Paper IV · Q4(b) (5 marks)	3×	319
96. High-intensity focused ultrasound — principle, MR- vs US-guided, and indications Asked in: Dec 2021 · Paper IV · Q5(b) (5 marks) · May 2024 · Paper IV · Q1 (10 marks)	2×	324
97. Interventional techniques for malignant hepatic masses Asked in: Dec 2021 · Paper IV · Q6 (10 marks)	1×	327
98. Biliary interventions and PTBD; interventional radiology in biliary strictures Asked in: Apr 2023 · Paper III · Q9 (10 marks) · May 2024 · Paper IV · Q9 (10 marks)	2×	332
99. Splenic artery embolisation — indications, technique and complications Asked in: Oct 2023 · Paper IV · Q1 (10 marks)	1×	338
100. Seldinger technique and radiological anatomy for femoral arterial puncture Asked in: Oct 2024 · Paper IV · Q4 (10 marks)	1×	341

C · High-yield list — whole book (asked 3× or more)

145. Ischaemic heart disease — cardiac MRI, viability, nuclear imaging and MDCT	5×	Vol II, p. 193
152. Plain radiograph in rheumatic and mitral valve disease and left atrial enlargement	5×	Vol II, p. 223
1. X-ray tube — construction, X-ray production and tube failure	4×	10
13. Dual-energy CT — principle, acquisition methods and applications including pulmonary	4×	45
44. Iodinated contrast media — classification, adverse reactions and management including emergency drugs and anaphylaxis	4×	149
74. Breast MRI — indications, technique, advantages, limitations, non-mass enhancement and benign vs malignant	4×	240

94. Embolic agents — classification, advantages, disadvantages and clinical applications	4×	315
126. Mediastinal compartments (ITMIG), anterior mediastinal masses and thymoma	4×	Vol II, p. 115
158. Acute mesenteric ischaemia — causes, imaging and endovascular management	4×	Vol II, p. 246
233. Ectopic pregnancy and first-trimester bleeding — ultrasound, algorithm and mimics	4×	Vol III, p. 225
237. Fetal growth restriction — ultrasound and Doppler (uterine artery, umbilical artery, MCA, ductus venosus)	4×	Vol III, p. 240
259. Acute ischaemic stroke — CT and MRI features, imaging algorithm and interventional radiology	4×	Vol IV, p. 9
8. Computed radiography and digital radiography — principles, advantages and disadvantages	3×	30
14. CT dose — CTDIvol, DLP and dose reduction in CT and radiography	3×	50
22. Colour Doppler — principle, Nyquist limit and artefacts and their prevention	3×	76
23. Ultrasound elastography — principles, techniques and applications including diffuse liver disease	3×	81
31. MRI artefacts, including motion artefacts and their reduction	3×	106
34. MRI safety — hazards, zoning of the MRI facility and safety considerations	3×	115
38. MR angiography — time-of-flight and phase-contrast principles, applications and pitfalls	3×	131
49. Ultrasound contrast agents — composition, generations, mechanism, applications, advantages and limitations	3×	169
51. Radiation protection — cardinal principles and protection of staff, patients and public	3×	176
56. Thermoluminescent dosimeter (TLD) badge — principles and uses	3×	188
70. Artificial intelligence in radiology	3×	226
82. Acute aortic syndrome and aortic dissection — classification, CT angiography and management	3×	266
86. Peripheral arterial disease — imaging modalities, CTA and MRA technique, and Doppler findings	3×	286
88. Renal artery stenosis — US, Doppler, MR angiography and intervention	3×	295
90. Varicose veins and venous incompetence — Doppler and interventional treatment	3×	301
92. Peripheral vascular malformations — diagnostic approach, Doppler and MRI, and interventional management	3×	308
95. Radiofrequency ablation — principle, indications, contraindications, complications and applications	3×	319
108. Acute pulmonary thromboembolism — pathophysiology, CT pulmonary angiography and imaging findings	3×	Vol II, p. 36
114. Haemoptysis — causes, imaging and interventional radiology	3×	Vol II, p. 59
117. Secondary pulmonary lobule, HRCT patterns of interstitial lung disease and usual interstitial pneumonia	3×	Vol II, p. 73
125. Cystic and cavitating lung lesions on CT — differential diagnosis	3×	Vol II, p. 111
137. Diaphragm — anatomy and traumatic injury on radiograph, US, CT and MRI; hernia vs eventration	3×	Vol II, p. 159
149. Congenital heart disease on the plain chest radiograph	3×	Vol II, p. 212
190. Segmental anatomy of the liver, triple-phase CT and imaging of hepatocellular carcinoma	3×	Vol III, p. 42
191. LI-RADS — categories, major and ancillary features, settings of use and role in management	3×	Vol III, p. 46
197. Budd–Chiari syndrome — causes, imaging, Doppler and interventional management	3×	Vol III, p. 70
206. Neonatal cholestasis and biliary atresia — US, MRI and scintigraphy	3×	Vol III, p. 102
207. Acute pancreatitis — radiography, CT and MRI	3×	Vol III, p. 108

208. Groove pancreatitis and mass-forming pancreatitis vs pancreatic adenocarcinoma	3×	Vol III, p. 111
210. Cystic pancreatic neoplasms — classification, imaging and side-branch IPMN	3×	Vol III, p. 121
216. Bosniak classification of renal cysts (version 2019) — criteria, significance and drawbacks	3×	Vol III, p. 146
217. Renal transplant — donor work-up, graft dysfunction and complications on US, Doppler and scintigraphy	3×	Vol III, p. 150
223. Carcinoma bladder — TNM/T staging with diagram, multiparametric MRI and VI-RADS	3×	Vol III, p. 175
228. Erectile dysfunction — penile Doppler technique, findings and limitations	3×	Vol III, p. 202
241. Placenta accreta spectrum and placental variants — US and MRI	3×	Vol III, p. 261
246. Acute pelvic pain in a young woman and ovarian torsion — causes and imaging	3×	Vol III, p. 285
249. Postmenopausal bleeding and endometrial carcinoma — imaging, differential diagnosis and staging	3×	Vol III, p. 301
260. Subarachnoid haemorrhage — causes, subarachnoid spaces, imaging evaluation and endovascular treatment of aneurysm	3×	Vol IV, p. 14
277. Epilepsy imaging — protocol, mesial temporal sclerosis, advanced MR and nuclear techniques	3×	Vol IV, p. 83
300. Sensorineural hearing loss in a child — inner ear anatomy and imaging work-up	3×	Vol IV, p. 177
314. Thyroid nodule — ultrasound evaluation and TI-RADS	3×	Vol IV, p. 229
325. Hyperparathyroidism — types, skeletal radiography, renal osteodystrophy and primary vs secondary	3×	Vol IV, p. 279
327. Rickets and osteomalacia — radiographic features	3×	Vol IV, p. 290
342. Cartilage imaging techniques and osteochondral lesions	3×	Vol IV, p. 342

PART 1

X-ray physics, equipment and radiography

1. X-ray tube — construction, X-ray production and tube failure

ASKED 4× · 10-mark answer

Asked in: Dec 2021 · Paper IV · Q1 (10 marks) · Dec 2022 · Paper IV · Q9 (10 marks) · Apr 2023 · Paper IV · Q10(b) (5 marks) · Jun 2025 · Paper IV · Q10(a) (5 marks)

Q: Draw a labeled diagram of X-Ray tube. Discuss the functioning of the X-ray tube. Discuss various causes of tube failure. [3+4+3]

Q: Describe the construction and principle of an X-ray tube. Discuss causes of X-ray tube failure. [4+3+3]

Q: Thermionic emission in X-ray production. [5]

Q: Discuss the construction of an X-ray tube with a neat labelled diagram and explain how X-rays are produced. [5]

SOURCE
CHR — Ch 2 Production of X Rays — §Production of X Rays — pp. 10–25

Construction of the X-ray tube

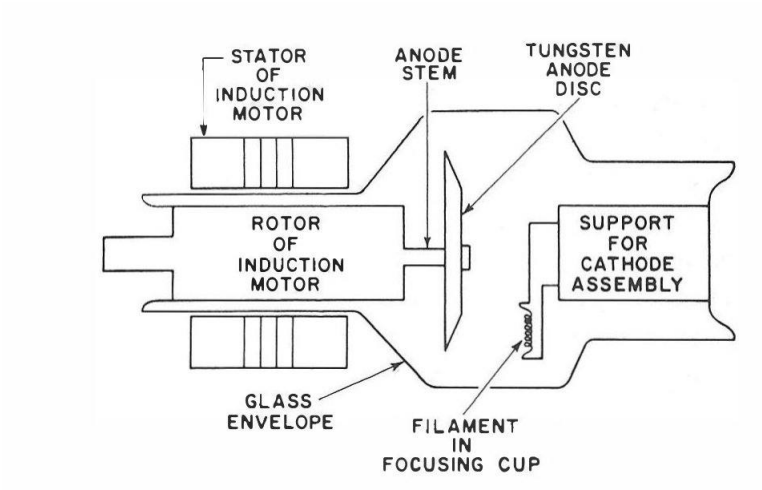

***Figure 2-6** — CHR, p. 16. The major components of a ro tating anode x-ray tube*

left: Cathode right: Anode

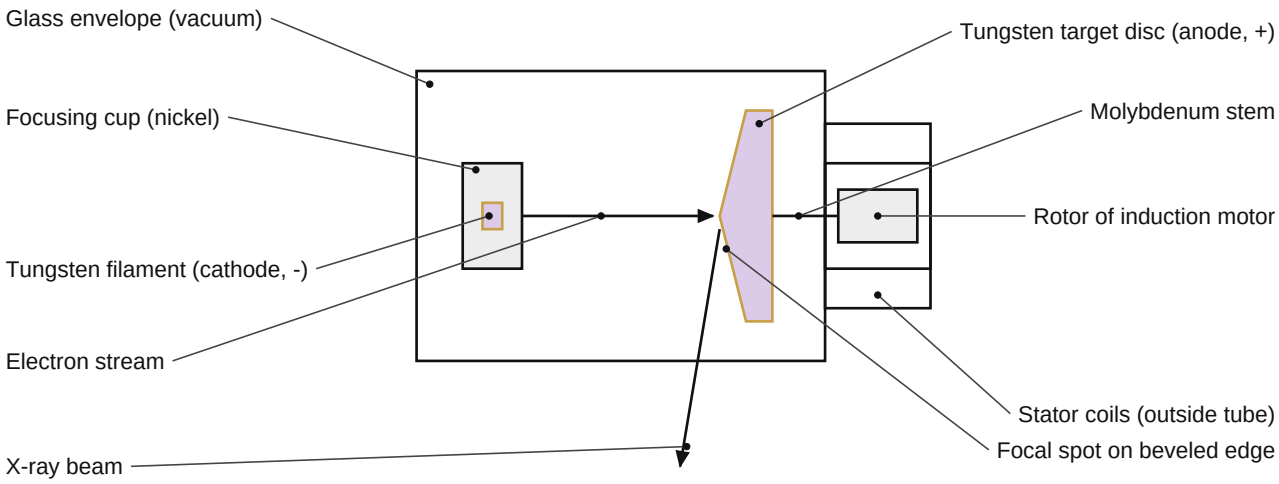

***Schematic (exam diagram): Rotating-anode X-ray tube (labelled).** Based on CHR, Fig. 2-6, pr.16 and text pr.10-16.*

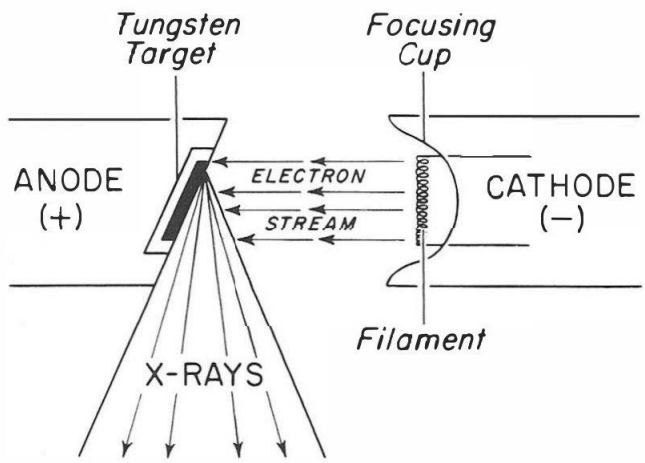

Figure 2-4 — CHR, p. 14. Lateral view of the cathode and anode of a stationary anode x-ray tube

Table 1: Components of the X-ray tube

Component	Material / feature	Function
Envelope	Pyrex glass; metal alloys sealed through the glass have a similar expansion coefficient	Holds the vacuum; the vacuum lets electron number and speed be controlled independently
Filament (cathode)	Tungsten wire about 0.2 mm thick, coiled; double filament, one used per exposure	Source of electrons by thermionic emission
Focusing cup	Nickel, at filament potential	Converges the electron stream onto the target in the required size and shape
Target	Tungsten (Z 74, melting point 3370°C)	Decelerates electrons and produces X-rays
Stationary anode	Tungsten plate 2–3 mm thick embedded in a copper mass	Copper increases heat capacity and speeds cooling
Rotating anode	Tungsten or W–Re disc with a beveled edge of 6–20°	Spreads the heat over a large track
Stem	Molybdenum, short	Poor heat conductor, so it shields the bearings
Stator and rotor	Stator coils outside the envelope; copper rotor inside	Induction motor that turns the anode
Housing	Lead-lined, filled with oil, with a metal bellows	Absorbs leakage radiation, insulates and cools, and allows for oil expansion

- **Metal/ceramic tube:** a metal envelope with ceramic insulators, bearings at both ends of the anode axle and anodes up to 2000 g. It gives less off-focus radiation, longer life and higher loading.
- **Grid-controlled tube:** the focusing cup is made negative to the filament, which pinches off the current and acts as a switch (cine).

Principle and functioning of the X-ray tube

- **Principle:** X-rays are produced when a fast stream of electrons is suddenly decelerated in the anode target.
- **Efficiency:** less than 1% of the electron energy becomes X-rays, and most becomes heat.
- **Sequence:**

1. The filament is heated and releases electrons by thermionic emission.
2. A high potential difference accelerates the electrons from cathode to anode.
3. The focusing cup converges them into the focal spot.
4. The electrons are stopped in the tungsten target, giving X-rays and heat.

- **Current direction:** electron flow is cathode to anode only.

Thermionic emission

- **Definition:** emission of electrons resulting from the absorption of thermal energy.
- **Mechanism:** a heated metal's electrons gain enough energy to escape the surface. The resulting electron cloud is the "Edison effect".

- **Filament heating:** about 10 V and 3–5 A heat the filament, and pure tungsten needs at least 2200°C.
- **Why tungsten:** it can be drawn into a strong thin wire, has a high melting point (3370°C) and vaporises little.
- **Space charge:** the electron cloud around the filament limits further emission. At equilibrium, returning electrons equal emitted electrons, and the cloud size depends on filament temperature.
- **Tube current (mA):** it equals the number of electrons per second from filament to target. 200 mA means twice the electrons, and twice the X-rays, of 100 mA.
- **Scale:** 100 mA is 6.25×10^{17} electrons per second.
- **Standby current:** about 5 mA, which is enough for fluoroscopy. An automatic boost circuit raises it before an exposure and lowers it afterwards.
- **Saturation voltage:** an example tube saturates at 40 kVp.
  - Below it the current is space-charge-limited.
  - Above it the current is emission (temperature) limited.
  - Resistors slightly reduce filament heating as kV rises, to keep mA constant.

Focal spot and beam behaviour

- **Line focus principle (1918):** the target is inclined so that the actual focal spot is large for heat loading but the apparent spot is small.
- **Apparent focal spot size:** it is directly related to the sine of the anode angle, and a smaller angle gives a smaller spot.
  - Anode angles range from 6 to 20°.
  - General radiography at 40 in. FFD uses no less than 15° because of the heel effect.
  - Common focal spot sizes are 0.3, 0.6, 1.0 and 1.2 mm.
- **Heel effect:** intensity is lower on the anode side because the target absorbs some photons.
  - In the book's example, exposure is 73% at the anode end and 105% at the cathode end of the film at 40 in..
  - The thicker part is placed toward the cathode.
  - The effect is less with larger FFD and smaller films.

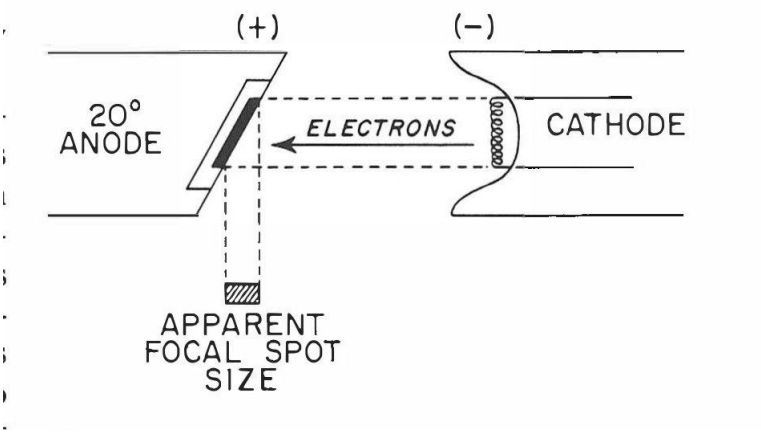

Figure 2-3 — CHR, p. 13. The line focus principle

Rotating anode

- **Rotation:** the anode rotates at about 3000–3600 rpm, and up to about 10,000 rpm with suitable circuits.
- **Heat-bearing area:** in the book's example, the instantaneous area is 14 mm² against a total track area of 1757 mm², a rise of about 125 times with the same apparent focal spot.
- **Drive:** the stator's magnetic field induces current in the copper rotor.
- **Start-up safety:** rotor acceleration takes 0.5–1 s, and a safety circuit blocks exposure until full speed.
- **Lubrication:** metallic lubricants (silver) are used because oil and graphite would destroy the vacuum.
- **Anode alloy:** about 90% tungsten and 10% rhenium resists surface roughening.

Heat management

- **Housing:** oil insulates and carries heat away. The bellows allows oil expansion and can trip a microswitch to stop exposures.
- **Heat unit:** HU = kVp × mA × s for single phase, and × 1.4 for constant potential.
- **Anode and housing cooling:**
  - The anode cools faster when it holds more heat.
  - In the book's example, the anode needs about 6 min to cool from 100,000 J to 10,000 J.
  - The housing needs about 30 min to dissipate 600,000 J.

Causes of X-ray tube failure

Table 2: Causes of tube failure

Cause	Mechanism	Result
Filament vaporisation	Prolonged heating thins the wire	Filament breaks and the tube is dead
Tungsten deposition ("sunburn")	Vaporised tungsten coats the glass	Beam filtered; arcing and puncture at high kVp
Loss of vacuum	Differential expansion breaks the glass–metal seal; lubricant vaporises or wears off	Uncontrolled current and energy
Anode surface roughening, pitting	Rapid surface heating and cooling causes thermal stress	Lower output from scatter and self-absorption
Single-exposure overload	Load beyond the rating chart; tungsten above 3000°C vaporises	Target damage; copper melts at 1070°C if the target is too small
Target bond failure	Tungsten and copper expand at different rates	Target peels from the anode
Rapid repeated exposures	Overheating of target surface, whole anode or housing	Damage; delay for cooling is needed
Bearing damage	Heat reaching the bearings makes them expand and bind; a long stem adds load	Rotor seizure or slow rotation
Housing oil overheating	Oil expands as it heats	Housing damage; the microswitch blocks exposures

- **Prevention:**
  - Use the manufacturer's rating charts.
  - Keep the filament at standby.
  - Allow cooling time between series.
  - Prefer tungsten–rhenium targets and slitted discs.

PEARLS

- X-rays arise from sudden deceleration of electrons in the target, and under 1% of the energy becomes X-rays.
- Thermionic emission means electron release by heat. The filament needs at least 2200°C, and mA is controlled by filament temperature.
- Above the saturation voltage, tube current depends on filament temperature and not on kV.
- Line focus: the apparent focal spot is proportional to the sine of the anode angle.
- Rotating anode: the heat-bearing area rises about 125 times in the book's example.
- Heel effect: intensity is lower toward the anode, so the thicker part goes at the cathode end.
- Exam trap: tungsten deposition on the glass causes arcing and a changed beam quality.
- Main failure causes: filament burn-out, loss of vacuum, anode pitting and overheating.

2. Rotating anode X-ray tube and its advantages

ASKED 2× · 5-mark answer

Asked in: Jun 2020 · Paper IV · Q1(a) (5 marks) · Dec 2020 · Paper IV · Q4(a) (5 marks)

Q: Rotating anode X-ray tube and its advantages. [5]

Q: Rotating anode tube. [5]

SOURCE

CHR — Ch 2 Production of X Rays — §Anode (Stationary, Rotating) — pp. 14–16

Principle

- The limiting factor in x-ray output became the tube, because the anode can only withstand a limited heat load.
- The rotating anode principle lets the tube withstand the heat of large exposures.
- It spreads the heat of an exposure over a large area of the anode.
- The electron beam strikes a constantly changing area, yet the effective focal spot appears stationary.

Construction

- The anode is a large disc of tungsten or a tungsten alloy.
- The disc has a beveled edge of 6–20°, which uses the line focus principle.
- Typical disc diameters are 75, 100 or 125 mm.
- The speed is theoretically about 3600 rpm. In practice it never reaches this, so 3000 rpm is assumed when calculating tube loading.
- Drive: **stator coils** outside the envelope induce current in the copper **rotor** of an induction motor.
- The **molybdenum stem** (melting point 2600° C, poor heat conductor) is a heat barrier protecting the bearings. It is kept short to limit the load on the bearings.
- Bearings use **metallic lubricants** (especially silver). Oil would vaporise and graphite would shed powder, and either would destroy the vacuum.
- Heat leaves the disc by radiation through the vacuum to the tube wall, then into the oil and housing.
- The rotor takes 0.5–1 s to reach full speed. A safety circuit blocks exposure until then.

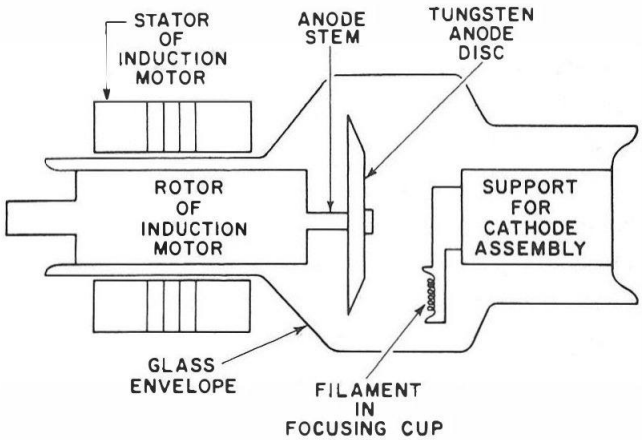

Figure 2-6 *— CHR, p. 16. The major components of a ro tating anode x-ray tube*

Advantages

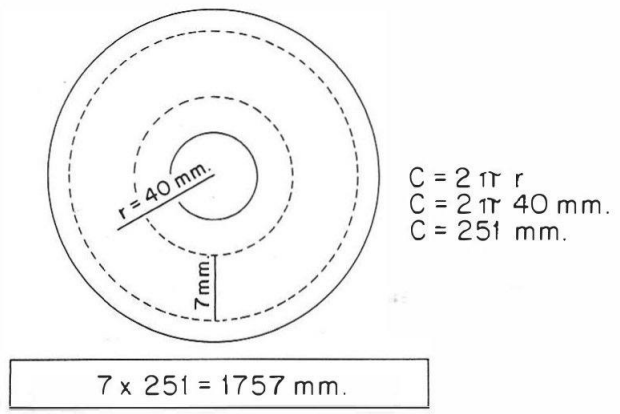

Figure 2-5 — CHR, p. 15. A rotating anode mcreases the total target area

Table 1: Stationary vs rotating anode

Feature	Stationary anode	Rotating anode
Target	Tungsten plate 2–3 mm thick in a copper mass	Large beveled tungsten disc
Heat handling	Absorbed by the target and conducted away by the massive copper	Spread over a track around the disc and radiated through the vacuum
Bombarded area	One small fixed area	Constantly changing area
Exposure capacity	Limited by heat	Large exposures tolerated

- The total loading area rises about 125-fold (14 → 1757 mm²).
- The apparent focal spot size is unchanged, so sharpness is kept.
- Each point on the disc faces the beam only briefly, so heat dissipates the rest of the time.
- It allows high-power generators and high tube output.

WORKED EXAMPLE

Effective loading area of a rotating anode (book example).

1. Electron beam on the target: 7 mm × 2 mm = 14 mm² (instantaneous area).
2. Mean track radius r = 40 mm, so the circumference C = 2πr = 2π × 40 mm ≈ 251 mm.
3. Total target area = 7 mm × 251 mm = 1757 mm².
4. Gain = 1757 mm² ÷ 14 mm² ≈ 125 times.
5. At 3600 rpm = 60 rev/s, one revolution takes 1/60 s. During a 1/60 s exposure the whole circumference passes under the beam.

PEARLS

- The rotating anode is a beveled tungsten disc driven by an induction motor (stator outside, rotor inside the vacuum). Its advantage is that it spreads the heat over a large track while the focal spot stays small.
- The molybdenum stem is a poor heat conductor and protects the bearings. Silver metallic lubricant preserves the vacuum.
- Load calculations assume 3000 rpm.
- A short delay (0.5–1 s) occurs before exposure because of rotor inertia.
- Limitation: heat stress roughens and pits the anode surface, which reduces x-ray output.

3. Photoelectric effect

ASKED 1× · 5-mark answer

Asked in: Dec 2020 · Paper IV · Q4(b) (5 marks)

Q: Photoelectric effect. [5]

SOURCE

CHR — Ch 4 Basic Interactions between X Rays and Matter — pp. 63–65
CHR — Ch 5 Attenuation — pp. 76–77, 83

Photoelectric effect

Process

- An incident photon with slightly more energy than a K-shell electron's binding energy ejects that electron. The photon disappears and gives up all its energy.
- The excess energy over the binding energy becomes the kinetic energy of the **photoelectron**. It is absorbed almost immediately because charged particles have little penetrating power.
- The K-shell void is filled at once, usually from the L shell, occasionally from the M shell and rarely by a free electron. The energy released leaves as an x-ray photon.

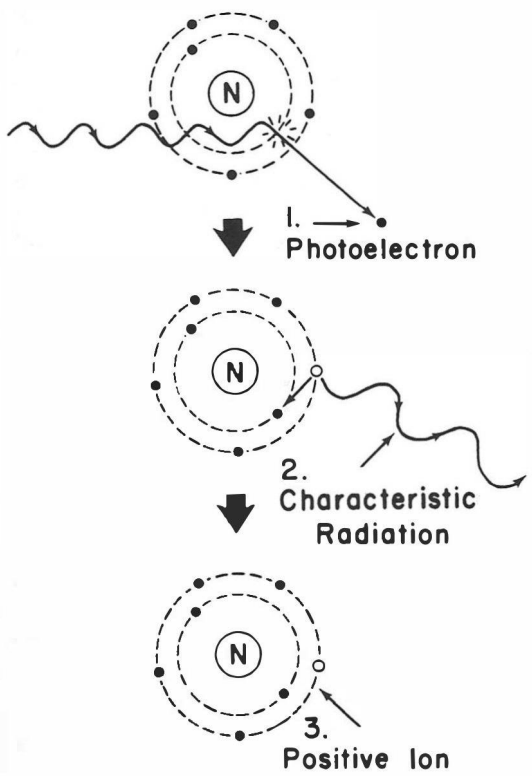

Figure 4-2 *— CHR, p. 63. Photoelectric effect*

- **Three end products:** characteristic radiation, a negative ion (the photoelectron) and a positive ion (an atom missing one electron).
- It cannot occur with a free (unbound) electron, so it is a "forbidden" interaction.

Probability of occurrence

Table 1: Factors governing the photoelectric effect

Factor	Rule	Example
Photon energy vs binding energy	Photon energy must exceed the binding energy. Probability is greatest when the two are nearly equal.	Iodine K-shell binding energy is 33.2 keV. A 33.0 keV photon cannot eject a K electron, and a 34 keV photon is far likelier to interact than a 100 keV photon
Photon energy	Probability ∝ 1/(energy)³ approximately	Falls precipitously as kVp rises
Atomic number	Probability ∝ (atomic number)³ approximately. Tightly bound electrons in high-Z elements react more readily	K-shell binding energy: calcium 4.04, iodine 33.2, barium 37.4, tungsten 69.5, lead 88.0 keV

- It is most likely with low-energy photons and high-Z absorbers, provided the photon energy exceeds the binding energy.

Characteristic radiation

- It is the same as the characteristic radiation of the x-ray tube. Only the method of ejecting the inner-shell electron differs: a photon here, a high-speed electron in the tube.
- Iodine example: L→K gives 33.2 − 4.9 = 28.3 keV, then M→L gives 4.3 keV.

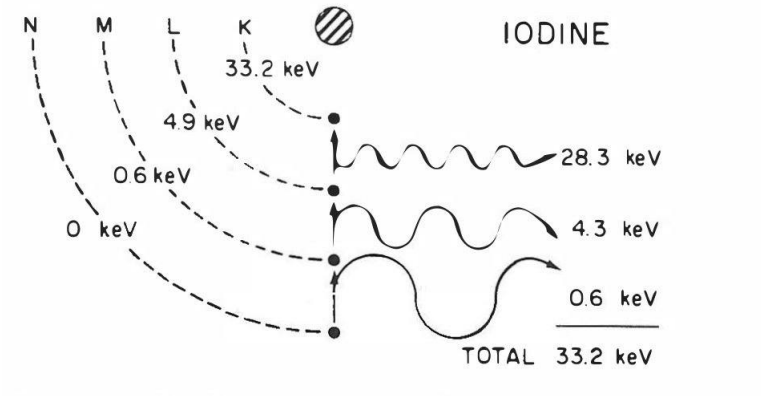

Figure 4-3 — CHR, p. 64. Characteristic radiation from io dine

- A free electron filling the K void in iodine gives a single 33.2 keV photon, the most energetic characteristic photon iodine can produce.
- Calcium emits a maximum of 4 keV and is absorbed within a few millimetres. Only iodine and barium emit characteristic radiation energetic enough to leave the patient and fog film.

Importance in diagnostic radiology

- **Advantage:** it produces no scatter and it enhances natural tissue contrast, because the (atomic number)³ dependence magnifies the bone–soft tissue difference.
- **Disadvantage:** the patient absorbs the photon's whole energy, so photoelectric reactions give the highest patient dose of any interaction.
- **Dose reduction:** use the highest kVp consistent with diagnostic quality.
- Photoelectric attenuation removes a beam much faster than Compton attenuation.
- **Photoelectric share of reactions at 20 / 60 / 100 keV**:
  - Water: 65% / 7% / 2%.
  - Compact bone: 89% / 31% / 9%.
  - Sodium iodide: 94% / 95% / 88%, so it predominates throughout the diagnostic range.
- Low-kVp techniques can separate fat from water, because their effective atomic numbers differ (5.9 vs 7.4).
- **K-edge effect:** with high-Z absorbers, transmission may fall as energy rises. Attenuation jumps abruptly once photon energy reaches the inner-shell binding energy.

> **DRAW IN THE EXAM**
> Photoelectric effect: incoming photon, K-shell ejection, photoelectron, and L→K characteristic photon.

PEARLS

- Photoelectric effect: the photon is totally absorbed, and a K-shell electron is ejected as a photoelectron.
- Probability ∝ $1/E^3$ and ∝ Z^3.
- Products: photoelectron, positive ion and characteristic radiation. There is no scatter.
- It gives high subject contrast (bone, iodine, barium) but the highest patient dose.
- Exam trap: the photon must exceed the K-shell binding energy (iodine 33.2 keV). Probability peaks just above this edge.
- Compton scatter, not photoelectric, causes almost all scatter radiation; photoelectric predominates at low kVp and high Z.

4. X-ray beam-restricting devices — types and uses

ASKED 2× · 5-mark answer

Asked in: Jun 2020 · Paper IV · Q1(b) (5 marks) · Apr 2023 · Paper IV · Q10(a) (5 marks)

Q: X-ray beam restricting device and their uses. [5]

Q: Beam restricting devices. [5]

SOURCE

CHR — Ch 7 X-Ray Beam Restrictors — pp. 93–94, 97–98

Types of beam restrictor

- **Definition:** a device attached to the opening of the tube housing to regulate the size and shape of the x-ray beam.
- Three types: **aperture diaphragms**, **cones and cylinders**, and **collimators**.

Table 1: Comparison of x-ray beam restrictors

Device	Construction	Advantage	Disadvantage
Aperture diaphragm	Lead sheet with a central hole; the hole sets beam size and shape	Simple; soft lead is easily altered	Large penumbra at the field periphery
Cone	Flared tube; the flare is usually greater than the beam flare	Fixes the field size	Only the base plate restricts the beam, so it acts as an aperture diaphragm
Cylinder	Barrel; restriction occurs at the far end	Less penumbra; extensions give better restriction	Very few field sizes; changing them is inconvenient
Collimator	Light-beam device with two sets of lead shutters	Infinite variety of rectangular fields; light beam shows the field	None stated; it is the best all-round restrictor

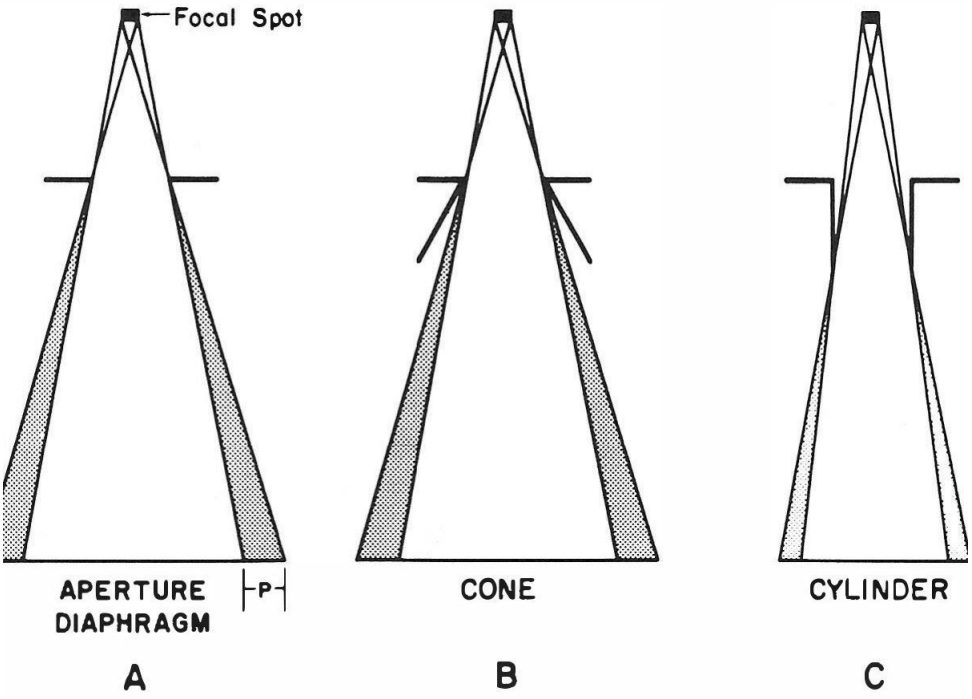

Figure 7-1 — CHR, p. 94. Aperture diaphragm (A), cone (B), and cylinder (C)

Aperture diaphragm, cone and cylinder

- **Penumbra** is the partially exposed field periphery. It "sees" only part of the focal spot, whereas the centre sees the whole spot.
- Penumbra is reduced by placing the diaphragm as far from the target as possible, usually by fixing it to the end of a cone.
- All three types allow only a few field sizes, so even a large assortment cannot match diagnostic needs.

WORKED EXAMPLE

Aperture size for a given field, using similar triangles (a/A = b/B):

1. Aperture distance A = 25 cm; target–film distance B = 100 cm; required field b = 15 cm.
2. a = 15 cm × 25/100 = **3.75 cm**.

Collimator

- It has two shutter sets (S1 and S2) that move together as a unit. The second shutter aligns with the first to "clean up" its penumbra.
- Each shutter has four or more lead plates moving in independent pairs, giving any square or rectangular field.
- A **light beam** illuminates the field. It is deflected by a mirror at **45°** in the x-ray path.
- The target and the light bulb must be exactly the same distance from the centre of the mirror, so that the light field coincides with the x-ray field.

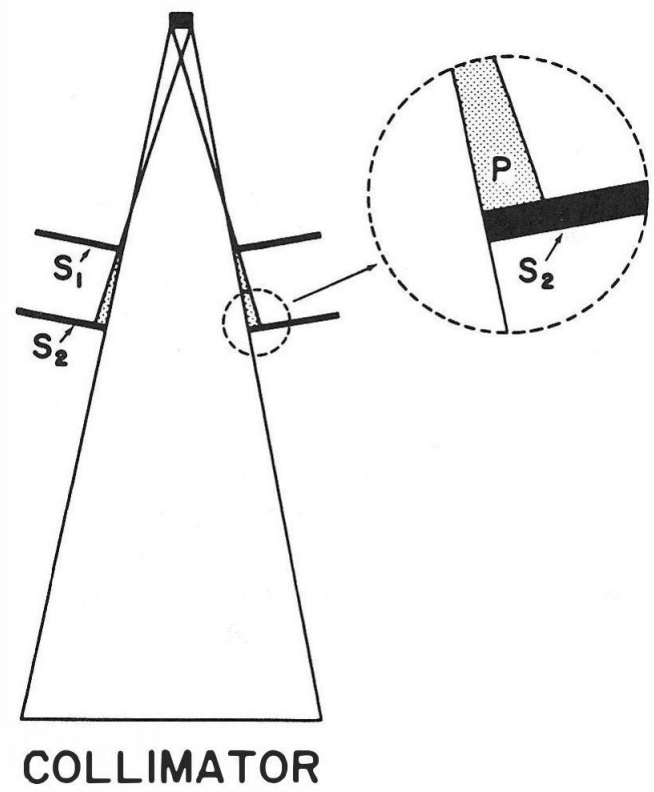

Figure 7-2 — CHR, p. 94. Alignment of collimator shutters

Uses

- **Patient protection:** a smaller area is exposed. Halving the beam diameter cuts patient exposure fourfold, because area is a square function.
- **Less scatter, better film quality:** scatter rises with field size and is near maximum by about 30 × 30 cm.
  - Collimation reduces scatter effectively only for small fields, so restrict the beam as much as possible.
  - Primary radiation at the film is independent of field size.
- **Exposure factors:** a smaller field gives less scatter and lower film density, so exposure factors must be increased to keep density constant.
- **Field shape matches the part:** the shape of the part examined should decide it, not the film or collimator. Round fields suit the gallbladder and paranasal sinuses.
  - A circular field wholly within the film is best for a round part.
- **Localisation:** the light beam allows accurate positioning on the patient.

PEARLS

- A beam restrictor regulates the size and shape of the x-ray beam; the types are aperture diaphragm, cone/cylinder and collimator.
- The collimator is the best all-round restrictor: variable rectangular fields plus a light-beam localiser.
- A 45° mirror, with target and bulb equidistant from it, keeps the light field and x-ray field congruent.
- Penumbra is least when the restrictor is far from the target; a cylinder is better than a cone.
- Halving the beam diameter gives a fourfold lower patient dose. A smaller field means less scatter, so exposure factors must be increased.

5. Scatter radiation and radiographic grids — structure, types, grid ratio, advantages and disadvantages

ASKED 2× · 10-mark answer

Asked in: Jun 2021 · Paper IV · Q4 (10 marks) · Jun 2022 · Paper IV · Q2 (10 marks)

Q: Describe the structure and types of radiographic grids. What is grid ratio? What are the advantages and disadvantages of using them? [4+2+4]

Q: What is scatter radiation? Describe various methods to reduce it. [5+5]

SOURCE

CHR — Ch 8 Grids — §Grids — pp. 99–117

AMP V1 — Ch 48 Radiation Hazards and Radiation Units — §Protection of Patient, Staff, and Public from Radiation — e.1863

AMP V1 — Ch 41 Fluoroscopy and Digital Subtraction Angiography — §Components of Fluoroscopic System — e.1647

What is scatter radiation

- Scatter is secondary radiation that arises from many points within the patient and travels in all directions. Primary radiation travels in the original beam axis and carries the image.
- It arises from **Compton reactions** in the patient, so the patient acts like a large light bulb radiating scatter.
- Effect: it degrades radiographic contrast. The larger the quantity of scatter, the poorer the contrast.
- Scatter increases with:
  - Higher beam energy. High-energy beams generate more scatter.
  - Larger irradiated volume. Scatter is directly proportional to the volume of tissue irradiated.
  - Smaller patient-to-film distance. The closer the patient is to the film, the greater the scatter per unit area.

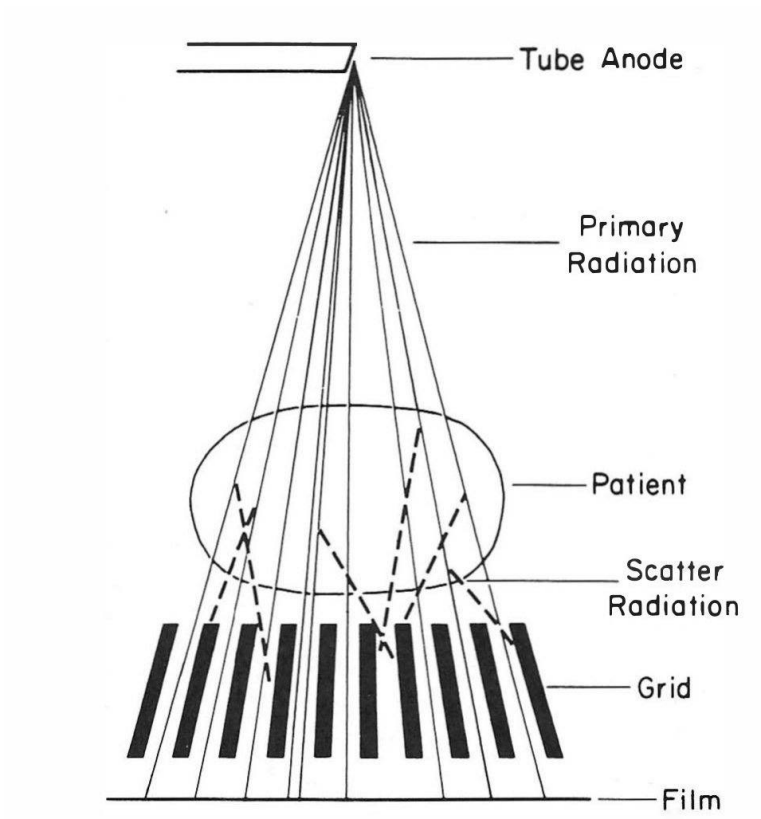

Figure 8-1 *— CHR, p. 99. Grid function*

Methods to reduce scatter

Table 1: Methods of reducing scatter radiation

Method	How it works	Key point
Collimation	Smaller irradiated field and volume	Less scatter and better image quality
Compression	Reduces body thickness and irradiated volume	Lower scatter and dose, better contrast; used in mammography
Antiscatter grid	Lead strips absorb scatter before it reaches the film	Most effective method for large fields
Air gap	Scattered photons miss the film	Comparable result with less patient exposure
Lower kVp	Less scatter generated	High-energy beams generate more scatter

Air gap technique

- Scatter falls because scattered photons miss the film. It is not due to filtration, so "air filtration" is a misnomer.
- Gap width is analogous to grid ratio. A larger gap removes more scatter, like a higher-ratio grid.
- Guidelines for choosing the gap:
  - A thicker part benefits more from a larger gap.
  - The first inch of gap improves contrast the most.
  - Sharpness deteriorates as the gap widens, so the focal-film distance is lengthened from 6 to 10 ft in chest radiography.
- A 10-in. gap with a 10-ft focal-film distance at 110–150 kVp gives satisfactory results.
- Exposure factors rise 1.8 times, but patient exposure is 0.77 of the grid technique, because grids absorb primary photons.
- Uses: chest radiography and magnification techniques.

Other points

- In children the grid may be removed, because less scatter arises from the smaller volume. This lowers the dose.
- In fluoroscopy, grids can be removed for a small field or when the intensifier is held away from the patient, which creates an air gap.

Structure of a radiographic grid

- A grid is a series of **lead foil strips** separated by x-ray-transparent spacers.
- Dr. Gustave Bucky invented it in 1913. It remains the most effective way of removing scatter from large fields.
- Mechanism: primary radiation is aligned with the strips and passes between them. Multidirectional scatter is mostly absorbed by the lead.
- The lead strips are about 0.05 mm thick. The interspaces are much thicker.
- **Interspace material** (supports the thin strips):
  - Aluminium: more precise manufacture and stronger. It absorbs more primary and more scatter, so patient exposure is higher and contrast is probably better.
  - Organic compound: the alternative; neither material is clearly better.
- **Lead content** (g/cm^2) is the weight of a 1-cm^2 piece of grid, ignoring interspace material. It indicates contrast-improving ability better than grid ratio.
- **Lines per inch** is the number of lead strips per inch of grid.
- Increasing lines per inch by thinning the strips or interspaces reduces lead content. A 133-line 10:1 grid improves contrast about as much as an 80-line 8:1 grid.

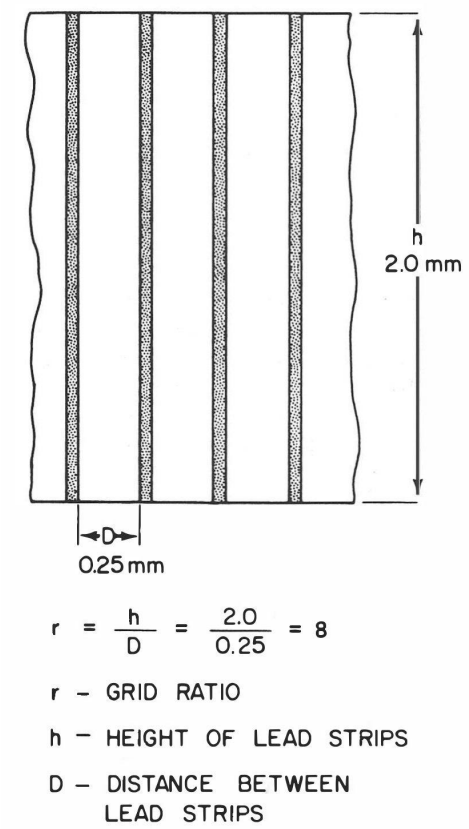

Figure 8-2 — CHR, p. 100. Cross section of a grid

Types of grids

Table 2: Types of radiographic grids

Basis	Type	Features
Pattern	**Linear**	Strips parallel along their length. The tube can be angled along the grid length without cutoff. Most tables use this type.
Pattern	**Crossed**	Two superimposed linear grids of the same focusing distance. Ratio is the sum of the two, so two 5:1 grids give 10:1. It cannot be used with oblique tube angulation.
Focusing	**Focused**	Strips angled to converge at a line (linear grid) or point (crossed grid) in space. Most grids are focused.
Focusing	**Parallel**	Strips parallel in cross-section, focused at infinity. Suited to small fields or long target-grid distances. Used in fluoroscopic spot-film devices.
Movement	**Stationary**	Fixed; no decentering error when positioned properly.
Movement	**Moving (Potter-Bucky)**	Reciprocating 1–3 cm during exposure to blur grid lines. Invented by Hollis Potter in 1920.
Cassette	**Grid-front cassette**	Grid built into the cassette front for portable work. Usually focused, ratio 4:1 to 8:1.

- **Focal distance** is the perpendicular distance from the grid to the convergent line or point.
- **Focusing range** is the distance range within which the grid works without significant loss of primary radiation.
  - It is wide for low-ratio grids and narrow for high-ratio grids. A 5:1 grid focused at 40 in. has a range of about 28–72 in. A 16:1 grid has a range of 38–42 in.

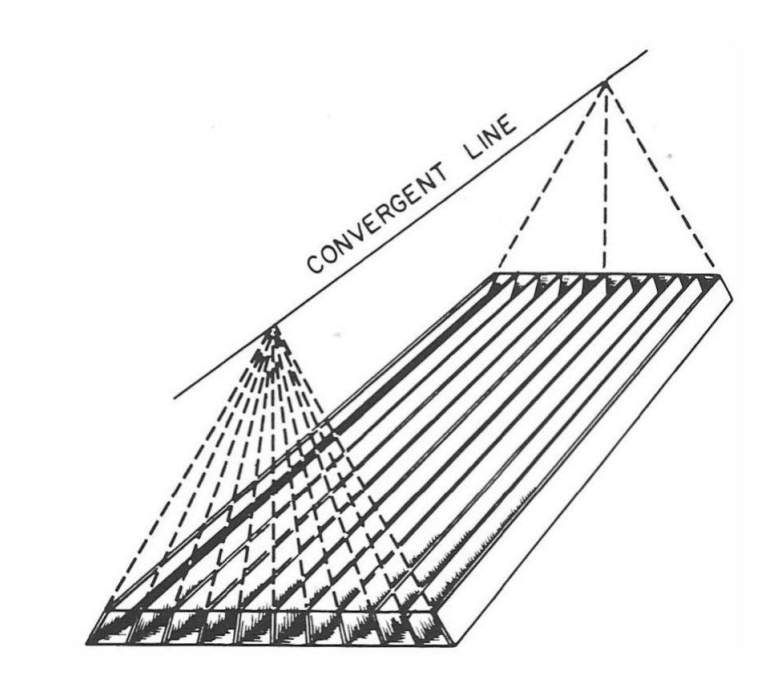

Figure 8-5 *— CHR, p. 101. Focused linear grid*

Grid ratio

- **Grid ratio = height of lead strips (h) ÷ distance between strips (D).**
- It is written as, for example, 10:1. The second number is always 1.
- Usual range is 4:1 to 16:1. Generally, the higher the ratio, the better the grid functions.
- Strip thickness is not part of the grid ratio.
- It is marked on the top of the grid by the manufacturer.
- Higher ratio gives a higher Bucky factor.
- Higher ratio gives a narrower focusing range.
- Higher ratio gives a greater risk of cutoff.

WORKED EXAMPLE

Grid in Figure 8-2: h = 2.0 mm, D = 0.25 mm, strip thickness d = 0.05 mm.

1. Grid ratio r = h ÷ D = 2.0 mm ÷ 0.25 mm = 8, so the grid is 8:1.
2. Lines/in. = 25.4 ÷ (D + d) = 25.4 ÷ (0.25 + 0.05) mm = 25.4 ÷ 0.30 ≈ 85 lines/in.
3. Calculated primary transmission = D ÷ (D + d) × 100 = 0.25 ÷ 0.30 × 100 ≈ 83%.
4. Cutoff for a 5:1 grid focused at f_0 = 72 in., with lateral decentering b = 2 in.: L = (r × b ÷ f_0) × 100 = (5 × 2 in. ÷ 72 in.) × 100 ≈ 14%.

Advantages and disadvantages

Advantages

- Most effective method of removing scatter from large fields.
- Improves film contrast by absorbing secondary radiation before it reaches the film.
- The contrast improvement factor K is the ratio of contrast with a grid to contrast without. It is the best test of grid performance.
- Moving grids remove grid lines from the film.
- High-ratio grids give maximum contrast.

Disadvantages

- **Increased patient dose:** the **Bucky factor** (incident ÷ transmitted radiation) shows how much exposure must rise. A factor of 5 means 5 times the exposure and dose.

- Bucky factors range from 3 to 7 depending on grid ratio.
- Part of the primary beam is lost. Measured primary transmission is 57–72.5%.
- **Grid cutoff** (loss of primary radiation, giving a light film) needs careful tube centering. It is greatest with high-ratio grids and short focus-grid distances. Causes:
  - Upside-down focused grid: dark central band, unexposed periphery.
  - Lateral decentering: uniformly light film, impossible to recognise on inspection. Also the commonest cutoff. Off-level (tilted) grids act the same.
  - Focus-grid distance decentering: centre unaffected, periphery light.
  - Combined lateral and distance decentering: film light on one side.
- Moving grids are costly, may fail or vibrate the table, and limit minimum exposure time.
- High-ratio grids give a poor return at low kVp.

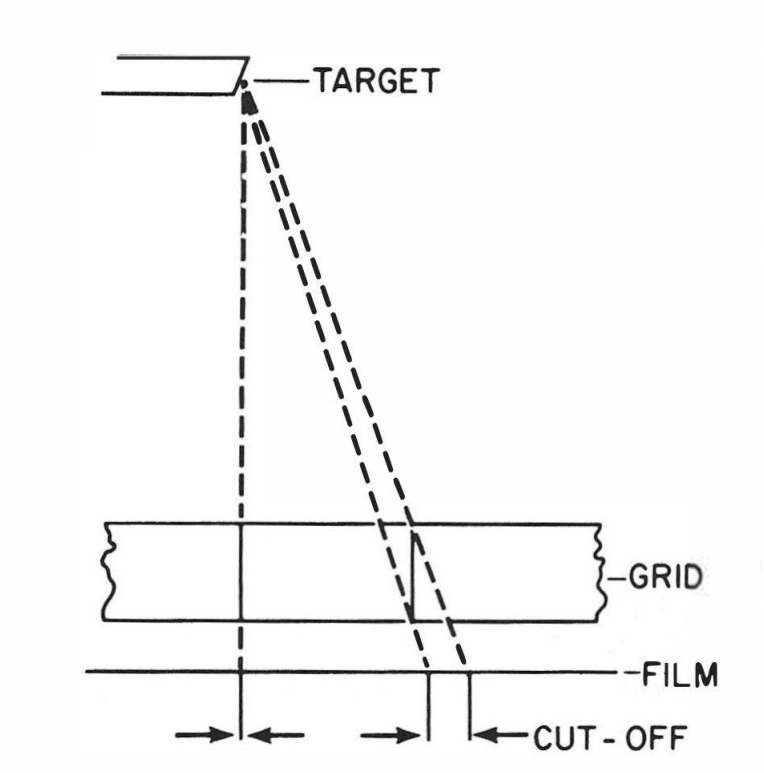

Figure 8-10 — CHR, p. 106. Grid cutoff

Grid selection

- Use 8:1 grids below 90 kVp and 12:1 above 90 kVp.
- Little extra scatter is removed beyond 8:1, and almost none between 12:1 and 16:1. So 12:1 is preferred to 16:1 for routine work.
- Use low-ratio grids and long focal distances when exact centering is not possible, as in portable radiography.
- Crossed grids are used only when scatter is heavy, as in biplane cerebral angiography.

PEARLS

- Scatter comes from Compton interactions in the patient. It lowers contrast but carries no image information.
- Grid ratio = lead strip height ÷ interspace distance. Strip thickness is not included.
- Crossed grid ratio = sum of the two linear ratios. It cannot be used with oblique tube angles.
- Bucky factor = incident ÷ transmitted radiation. It equals the exposure and dose multiplier.
- Most common cutoff is lateral decentering, which gives a uniformly light film.
- Air gap: scatter misses the film (not filtration). Dose is lower than with a grid, but the focal-film distance must be longer.
- Exam trap: contrast improvement factor K, not grid ratio, is the best test of grid performance.

6. Rare-earth intensifying screens

ASKED 1× · 5-mark answer

Asked in: Dec 2020 · Paper IV · Q6(a) (5 marks)

Q: Rare earth screens. [5]

SOURCE

CHR — Ch 9 Luminescent Screens — pp. 118, 124–127, 129–130
CHR — Ch 11 Photographic Characteristics of X-Ray Film — p. 161
CHR — Ch 14 The Radiographic Image — p. 206
AMP V1 — Ch 49 Radiation Protection — §Fluoroscopy X-ray Equipment — e.1887

Definition

- **Rare-earth screens** are intensifying screens whose phosphor contains a rare-earth element, replacing calcium tungstate ($CaWO_4$).
- The rare-earth group is the **lanthanide series**, atomic numbers 57 (lanthanum) to 71 (lutetium). Lanthanum (La) and gadolinium (Gd) are used in screens.
- Yttrium (Z 39) is not a rare earth but behaves similarly.
- Rare-earth screens have been commercially available since about 1973.

Phosphors

- **Gd_2O_2S:Tb** (terbium-activated gadolinium oxysulfide) emits green light.
- **LaOBr:Tm** (thulium-activated lanthanum oxybromide) emits blue light.
- **Y_2O_2S:Tb** (yttrium oxysulfide) behaves like Gd_2O_2S. Its conversion efficiency is about the same as gadolinium's.
- **Yttrium tantalate ($YTaO_4$:Tm, $YTaO_4$:Nb)** emits ultraviolet/blue light.
- Rare-earth phosphors do not fluoresce properly when pure. Gd_2O_2S gives maximum fluorescence when about 0.3% of the gadolinium is replaced by terbium (the activator).

Why they are faster than calcium tungstate

- Screen speed can be raised in three ways: a thicker layer, a higher conversion efficiency, or a higher absorption.
- **Higher conversion efficiency**
  - $CaWO_4$ converts about 5% of absorbed x-ray energy to light, against about 20% for rare earths.
  - One absorbed photon gives about 1000 light photons in $CaWO_4$ and about 4000 in a rare-earth screen.
- **Higher absorption**
  - A pair of par-speed $CaWO_4$ screens absorbs about 20% of the beam, high-speed $CaWO_4$ about 40%, and rare-earth screens about 60%.
  - The gain comes from **K-edge matching**. The K edges of Gd (50.2 keV), La (about 39 keV) and Ba lie near the peak intensity of the diagnostic beam.
  - W has a higher Z, but its K edge is at 69.5 keV.
  - Gd gives a four- to five-fold absorption advantage over $CaWO_4$ between 50 and 70 keV.
  - La "closes the window" between 39 and 50 keV, which is why it is added to some screens.

CLINICA
PUBLICATION

DNB EXIT EXAM · SOLVED PREVIOUS-YEAR QUESTION PAPERS

DNB Radiodiagnosis

Solved Previous-Year Questions

VOLUME II

Chest, Cardiac and Gastrointestinal Tract

Answers are written from six radiology textbooks — Grainger & Allison 7e, Rumack & Levine 6e, Chapman & Nakielny 7e, Christensen 4e, AIIMS-MAMC-PGI 3e and Core Radiology 2e — one lead book per question, with the chapter and pages named in each answer, and from current reporting systems, guidelines and Indian regulations found on official sites, listed in the Web-Sourced Facts Register.

REVIEWED BY

Dr Hemant Kumar
DNB Radiodiagnosis

Dr. Khusbo Singh
DNB Radiodiagnosis

UPDATED TILL OCTOBER 2026

CLINICA PUBLICATION
www.clinicapublication.com

Index

HOW TO USE

Each answer groups every year and paper the question was asked in and is written to the union of what those versions asked. The badge shows how often it was asked. The SOURCE box under each question names the textbook chapters and pages used and any current guideline or web source [W#]; every [W#] is also listed in the register at the end. Book images carry their own figure number and page; anatomy and diagram questions also carry a schematic exam diagram you can reproduce in 2–3 minutes. A lists the parts, B this volume question by question, C the high-yield topics (asked 3× or more).

A · Parts

Part 12 — Chest — lungs, airways, pleura, mediastinum and diaphragm	38 answers	9
Part 13 — Cardiac and coronary imaging	16 answers	170
Part 14 — Gastrointestinal tract, peritoneum, mesentery and retroperitoneum	27 answers	233

B · This volume, question by question

101. Bronchopulmonary segments; hilum overlay, hilum convergence and cervicothoracic signs Asked in: Jun 2020 · Paper II · Q3 (10 marks) · Jun 2021 · Paper II · Q1 (10 marks)	2×	9
102. Chest radiograph views — technique and indications of any five Asked in: Dec 2021 · Paper II · Q6 (10 marks)	1×	13
103. Calcifications on the chest radiograph — differential diagnosis Asked in: Dec 2021 · Paper II · Q9(b) (5 marks)	1×	16
104. ICU chest radiograph — tubes, lines and catheters Asked in: Jun 2020 · Paper II · Q10 (10 marks)	1×	19
105. Lobar collapse — types, general signs and localising signs Asked in: Jun 2020 · Paper II · Q5 (10 marks)	1×	22
106. Unilateral opaque hemithorax — differential diagnosis and imaging evaluation in an adult Asked in: Apr 2023 · Paper II · Q7 (10 marks) · Jun 2025 · Paper II · Q5(a) (4 marks)	2×	27
107. Unilateral hyperlucent (hypertransradiant) hemithorax Asked in: Dec 2022 · Paper II · Q3 (10 marks) · Oct 2024 · Paper II · Q6 (10 marks)	2×	32
108. Acute pulmonary thromboembolism — pathophysiology, CT pulmonary angiography and imaging findings Asked in: Jun 2020 · Paper II · Q1 (10 marks) · Apr 2023 · Paper II · Q1 (10 marks) · Jun 2025 · Paper II · Q2 (10 marks)	3×	36
109. Chronic pulmonary thromboembolism — CT features Asked in: Dec 2021 · Paper II · Q7(b) (5 marks)	1×	40
110. Suspected pulmonary thromboembolism in pregnancy — role of imaging Asked in: Oct 2024 · Paper II · Q3 (10 marks)	1×	42
111. Pulmonary oedema — definition, pathophysiology, causes and radiographic findings Asked in: Dec 2020 · Paper II · Q10 (10 marks) · Oct 2023 · Paper II · Q8 (10 marks)	2×	46
112. Pulmonary arteriovenous malformation — imaging and embolisation Asked in: Jun 2025 · Paper II · Q4 (10 marks)	1×	51
113. Vasculitides — classification and pulmonary vasculitis imaging Asked in: Dec 2022 · Paper II · Q10 (10 marks)	1×	56
114. Haemoptysis — causes, imaging and interventional radiology Asked in: Dec 2020 · Paper II · Q3 (10 marks) · Jun 2022 · Paper II · Q8 (10 marks) · Oct 2023 · Paper II · Q7 (10 marks)	3×	59
115. Bronchial artery anatomy and bronchial artery embolisation Asked in: Dec 2020 · Paper IV · Q7 (10 marks) · Dec 2025 · Paper IV · Q1(a) (5 marks)	2×	64
116. Ground-glass opacity — pathophysiology and differential diagnosis, and the crazy-paving pattern Asked in: Dec 2022 · Paper II · Q8 (10 marks) · Dec 2025 · Paper II · Q1(b) (5 marks)	2×	69
117. Secondary pulmonary lobule, HRCT patterns of interstitial lung disease and usual interstitial pneumonia Asked in: Apr 2023 · Paper II · Q2 (10 marks) · Jun 2025 · Paper II · Q7 (10 marks) · Dec 2025 · Paper II · Q1(a) (5 marks)	3×	73

118. Thoracic manifestations of collagen vascular diseases Asked in: Apr 2023 · Paper II · Q6 (10 marks)	1×	80
119. COVID-19 — chest imaging indications, CT protocol, pathophysiology and findings Asked in: Jun 2020 · Paper II · Q6 (10 marks) · Dec 2021 · Paper II · Q2 (10 marks)	2×	84
120. Pneumonia patterns in immunocompromised patients and fungal infections including aspergillosis Asked in: Dec 2020 · Paper II · Q2 (10 marks) · Dec 2025 · Paper II · Q5(a) (5 marks)	2×	87
121. Pulmonary hydatid disease — life cycle of Echinococcus and imaging Asked in: Dec 2021 · Paper II · Q5 (10 marks)	1×	92
122. Solitary pulmonary nodule — definition, differential diagnosis in adults and children, benign vs malignant features Asked in: Jun 2021 · Paper II · Q9 (10 marks) · May 2024 · Paper II · Q7 (10 marks)	2×	96
123. Multiple pulmonary nodules — causes and distinctive features Asked in: Jun 2022 · Paper II · Q4 (10 marks)	1×	101
124. Carcinoma lung — pathology, imaging evaluation, current TNM staging and role of FDG PET Asked in: Jun 2021 · Paper II · Q2 (10 marks) · Dec 2025 · Paper II · Q2 (10 marks)	2×	105
125. Cystic and cavitating lung lesions on CT — differential diagnosis Asked in: Dec 2021 · Paper II · Q9(a) (5 marks) · Jun 2022 · Paper II · Q7 (10 marks) · Jun 2025 · Paper II · Q6 (10 marks)	3×	111
126. Mediastinal compartments (ITMIG), anterior mediastinal masses and thymoma Asked in: Dec 2020 · Paper II · Q9 (10 marks) · Jun 2021 · Paper II · Q3 (10 marks) · Jun 2025 · Paper II · Q1 (10 marks) · Dec 2025 · Paper II · Q5(b) (5 marks)	4×	115
127. Middle mediastinal mass — differential diagnosis (ITMIG compartments) Asked in: Dec 2022 · Paper II · Q4 (10 marks)	1×	120
128. Posterior mediastinal masses — paediatric masses and approach Asked in: Dec 2021 · Paper II · Q1 (10 marks) · Oct 2023 · Paper II · Q5 (10 marks)	2×	125
129. Hilar lymph node enlargement — causes and CT differentiation Asked in: Dec 2021 · Paper II · Q4 (10 marks)	1×	130
130. MDCT airway reconstructions and intraluminal tracheobronchial lesions Asked in: Jun 2021 · Paper II · Q7 (10 marks)	1×	135
131. Developmental lung anomalies and pulmonary sequestration Asked in: Apr 2023 · Paper II · Q8 (10 marks) · Oct 2023 · Paper II · Q6 (10 marks)	2×	139
132. Neonatal respiratory distress and hyaline membrane disease Asked in: Dec 2020 · Paper II · Q7 (10 marks) · Dec 2025 · Paper II · Q10(b) (5 marks)	2×	143
133. Lung and pleural ultrasound including in the emergency department Asked in: Jun 2022 · Paper II · Q2 (10 marks) · Apr 2023 · Paper II · Q5(b) (5 marks)	2×	147
134. Pneumothorax — supine radiograph and ultrasound technique and signs Asked in: May 2024 · Paper II · Q3(b) (5 marks) · Oct 2024 · Paper IV · Q2 (10 marks)	2×	150
135. Pleural mesothelioma — imaging Asked in: Jun 2025 · Paper II · Q5(b) (6 marks)	1×	154
136. Pulmonary MRI Asked in: Apr 2023 · Paper IV · Q4(b) (5 marks)	1×	157
137. Diaphragm — anatomy and traumatic injury on radiograph, US, CT and MRI; hernia vs eventration Asked in: Jun 2020 · Paper II · Q7 (10 marks) · Dec 2020 · Paper II · Q8 (10 marks) · May 2024 · Paper II · Q2 (10 marks)	3×	159
138. Raised left hemidiaphragm — differential diagnosis and work-up Asked in: Oct 2024 · Paper II · Q4 (10 marks)	1×	164
139. Coronary artery anatomy and the role and technique of CT coronary angiography Asked in: Jun 2020 · Paper II · Q8 (10 marks) · Oct 2023 · Paper II · Q1 (10 marks)	2×	170
140. Coronary artery variants and malignant (dangerous) anomalies Asked in: May 2024 · Paper II · Q1 (10 marks)	1×	175
141. Limitations of retrospectively ECG-gated coronary CT and strategies to overcome them Asked in: Apr 2023 · Paper IV · Q6 (10 marks)	1×	179

142. Coronary artery calcium scoring Asked in: Dec 2025 · Paper II · Q4(a) (5 marks)	1×	182
143. Acute chest pain in emergency — CT protocol, triple rule-out and likely causes Asked in: Dec 2021 · Paper II · Q3 (10 marks) · Jun 2022 · Paper II · Q3 (10 marks)	2×	184
144. Non-cardiac chest pain — causes and role of imaging Asked in: May 2024 · Paper II · Q4 (10 marks)	1×	187
145. Ischaemic heart disease — cardiac MRI, viability, nuclear imaging and MDCT Asked in: Jun 2020 · Paper II · Q2 (10 marks) · Dec 2020 · Paper II · Q6 (10 marks) · Jun 2021 · Paper II · Q5(b) (5 marks) · Dec 2021 · Paper II · Q8(b) (5 marks) · Dec 2022 · Paper II · Q2 (10 marks)	5×	193
146. Cardiac MRI — indications, sequences (dark and white blood) and systematic interpretation Asked in: Jun 2021 · Paper II · Q5(a) (5 marks) · Jun 2025 · Paper II · Q8 (10 marks)	2×	198
147. Cardiac MRI in ischaemic and non-ischaemic cardiomyopathy and myocarditis Asked in: Oct 2024 · Paper II · Q10(b) (5 marks) · Dec 2025 · Paper II · Q7 (10 marks)	2×	202
148. Coarctation of the aorta — rib notching, radiography, CT and MRI, and intervention Asked in: Dec 2020 · Paper II · Q1 (10 marks)	1×	207
149. Congenital heart disease on the plain chest radiograph Asked in: Dec 2021 · Paper II · Q7(a) (5 marks) · Apr 2023 · Paper II · Q4 (10 marks) · Jun 2025 · Paper II · Q3(a) (5 marks)	3×	212
150. Tetralogy of Fallot — pathophysiology, associations, radiography and MRI Asked in: Dec 2022 · Paper II · Q9 (10 marks) · Dec 2025 · Paper II · Q4(b) (5 marks)	2×	215
151. Segmental approach to CT in congenital heart disease Asked in: May 2024 · Paper II · Q5 (10 marks)	1×	220
152. Plain radiograph in rheumatic and mitral valve disease and left atrial enlargement Asked in: Jun 2021 · Paper II · Q8(b) (5 marks) · Dec 2021 · Paper II · Q10(a) (5 marks) · Apr 2023 · Paper II · Q9(a) (5 marks) · May 2024 · Paper II · Q3(a) (5 marks) · Oct 2024 · Paper II · Q10(a) (5 marks)	5×	223
153. Constrictive pericarditis — CT features Asked in: Jun 2021 · Paper II · Q8(a) (5 marks)	1×	226
154. Cardiac tumours — imaging Asked in: Jun 2022 · Paper II · Q5 (10 marks)	1×	228
155. Plain radiograph in the acute abdomen Asked in: Jun 2020 · Paper III · Q10(a) (5 marks)	1×	233
156. Acute right iliac fossa pain in a child — causes and imaging Asked in: May 2024 · Paper II · Q10 (10 marks)	1×	236
157. Acute epigastric pain in an adult — differential diagnosis and imaging Asked in: May 2024 · Paper III · Q3 (10 marks)	1×	241
158. Acute mesenteric ischaemia — causes, imaging and endovascular management Asked in: Jun 2020 · Paper III · Q8 (10 marks) · Dec 2020 · Paper III · Q4 (10 marks) · Jun 2022 · Paper III · Q9 (10 marks) · Jun 2025 · Paper III · Q1 (10 marks)	4×	246
159. Small bowel obstruction — role of radiography, enteroclysis, US, CT and MRI Asked in: Oct 2023 · Paper III · Q1 (10 marks)	1×	250
160. Internal hernias — types and imaging Asked in: Jun 2020 · Paper III · Q3 (10 marks)	1×	256
161. Lower gastrointestinal bleeding — causes, imaging and intervention Asked in: Apr 2023 · Paper III · Q5 (10 marks)	1×	259
162. Dysphagia, barium swallow and oesophageal motility disorders including achalasia Asked in: Dec 2020 · Paper III · Q7 (10 marks) · Dec 2021 · Paper III · Q8(a) (5 marks)	2×	260
163. Endoscopic ultrasound in oesophageal neoplasms Asked in: May 2024 · Paper IV · Q10(b) (5 marks)	1×	265
164. MR enterography and MR enteroclysis — technique and indications Asked in: Dec 2021 · Paper III · Q8(b) (5 marks) · May 2024 · Paper IV · Q4 (10 marks)	2×	266
165. CT enterography Asked in: Apr 2023 · Paper IV · Q9(b) (5 marks)	1×	270

166. Ileocaecal tuberculosis — barium and CT features and differentiation from Crohn disease Asked in: Jun 2021 · Paper III · Q4 (10 marks) · Dec 2025 · Paper III · Q7(b) (5 marks)	2×	273
167. Crohn disease — CT enterography technique and MRI evaluation, enteric and extra-enteric features Asked in: May 2024 · Paper III · Q1 (10 marks) · Dec 2025 · Paper III · Q10(b) (5 marks)	2×	276
168. Gastrointestinal and small bowel lymphoma — pathology, imaging and differential diagnosis Asked in: Jun 2021 · Paper III · Q10 (10 marks) · Jun 2025 · Paper III · Q2 (10 marks)	2×	282
169. Gastrointestinal stromal tumour — CT in diagnosis and follow-up Asked in: Dec 2021 · Paper III · Q10(b) (5 marks) · Dec 2025 · Paper III · Q7(a) (5 marks)	2×	287
170. CT colonography — role, technique, contraindications and polyp findings Asked in: Dec 2021 · Paper III · Q3 (10 marks)	1×	289
171. Colonic polypoid lesions — classification and cross-sectional imaging of colonic carcinoma Asked in: Oct 2023 · Paper III · Q4 (10 marks)	1×	295
172. Double-contrast barium enema — technique Asked in: Jun 2025 · Paper IV · Q2(a) (5 marks)	1×	299
173. Perianal fistula — anorectal anatomy, classification and MRI Asked in: Dec 2020 · Paper III · Q5 (10 marks) · Oct 2024 · Paper III · Q9 (10 marks)	2×	300
174. Retroperitoneum — cross-sectional anatomy, approach to a primary mass and liposarcoma Asked in: Jun 2021 · Paper III · Q7 (10 marks) · Dec 2022 · Paper III · Q6 (10 marks)	2×	304
175. Mesenteric tumours — differential diagnosis and imaging Asked in: Oct 2024 · Paper III · Q3 (10 marks)	1×	309
176. Necrotising enterocolitis — imaging Asked in: Jun 2022 · Paper III · Q6 (10 marks)	1×	312
177. Hirschsprung disease — aetiopathogenesis, imaging and differential diagnosis Asked in: Dec 2022 · Paper III · Q9 (10 marks)	1×	316
178. Intestinal malrotation and midgut volvulus Asked in: Apr 2023 · Paper III · Q2 (10 marks)	1×	320
179. Hypertrophic pyloric stenosis — risk factors, presentation and imaging Asked in: May 2024 · Paper III · Q2 (10 marks) · Dec 2025 · Paper III · Q5(a) (5 marks)	2×	326
180. Liver mass in a 2-year-old — imaging differentials and biochemical aids Asked in: Dec 2022 · Paper III · Q8 (10 marks)	1×	330
181. Paediatric abdominal malignancies and Wilms tumour — imaging and differential diagnosis Asked in: Oct 2024 · Paper III · Q6 (10 marks) · Jun 2025 · Paper III · Q5 (10 marks)	2×	334

C · High-yield list — whole book (asked 3× or more)

145. Ischaemic heart disease — cardiac MRI, viability, nuclear imaging and MDCT	5×	193
152. Plain radiograph in rheumatic and mitral valve disease and left atrial enlargement	5×	223
1. X-ray tube — construction, X-ray production and tube failure	4×	Vol I, p. 10
13. Dual-energy CT — principle, acquisition methods and applications including pulmonary	4×	Vol I, p. 45
44. Iodinated contrast media — classification, adverse reactions and management including emergency drugs and anaphylaxis	4×	Vol I, p. 149
74. Breast MRI — indications, technique, advantages, limitations, non-mass enhancement and benign vs malignant	4×	Vol I, p. 240
94. Embolic agents — classification, advantages, disadvantages and clinical applications	4×	Vol I, p. 315
126. Mediastinal compartments (ITMIG), anterior mediastinal masses and thymoma	4×	115
158. Acute mesenteric ischaemia — causes, imaging and endovascular management	4×	246
233. Ectopic pregnancy and first-trimester bleeding — ultrasound, algorithm and mimics	4×	Vol III, p. 225
237. Fetal growth restriction — ultrasound and Doppler (uterine artery, umbilical artery, MCA, ductus venosus)	4×	Vol III, p. 240
259. Acute ischaemic stroke — CT and MRI features, imaging algorithm and interventional radiology	4×	Vol IV, p. 9

8. Computed radiography and digital radiography — principles, advantages and disadvantages	3×	Vol I, p. 30
14. CT dose — CTDIvol, DLP and dose reduction in CT and radiography	3×	Vol I, p. 50
22. Colour Doppler — principle, Nyquist limit and artefacts and their prevention	3×	Vol I, p. 76
23. Ultrasound elastography — principles, techniques and applications including diffuse liver disease	3×	Vol I, p. 81
31. MRI artefacts, including motion artefacts and their reduction	3×	Vol I, p. 106
34. MRI safety — hazards, zoning of the MRI facility and safety considerations	3×	Vol I, p. 115
38. MR angiography — time-of-flight and phase-contrast principles, applications and pitfalls	3×	Vol I, p. 131
49. Ultrasound contrast agents — composition, generations, mechanism, applications, advantages and limitations	3×	Vol I, p. 169
51. Radiation protection — cardinal principles and protection of staff, patients and public	3×	Vol I, p. 176
56. Thermoluminescent dosimeter (TLD) badge — principles and uses	3×	Vol I, p. 188
70. Artificial intelligence in radiology	3×	Vol I, p. 226
82. Acute aortic syndrome and aortic dissection — classification, CT angiography and management	3×	Vol I, p. 266
86. Peripheral arterial disease — imaging modalities, CTA and MRA technique, and Doppler findings	3×	Vol I, p. 286
88. Renal artery stenosis — US, Doppler, MR angiography and intervention	3×	Vol I, p. 295
90. Varicose veins and venous incompetence — Doppler and interventional treatment	3×	Vol I, p. 301
92. Peripheral vascular malformations — diagnostic approach, Doppler and MRI, and interventional management	3×	Vol I, p. 308
95. Radiofrequency ablation — principle, indications, contraindications, complications and applications	3×	Vol I, p. 319
108. Acute pulmonary thromboembolism — pathophysiology, CT pulmonary angiography and imaging findings	3×	36
114. Haemoptysis — causes, imaging and interventional radiology	3×	59
117. Secondary pulmonary lobule, HRCT patterns of interstitial lung disease and usual interstitial pneumonia	3×	73
125. Cystic and cavitating lung lesions on CT — differential diagnosis	3×	111
137. Diaphragm — anatomy and traumatic injury on radiograph, US, CT and MRI; hernia vs eventration	3×	159
149. Congenital heart disease on the plain chest radiograph	3×	212
190. Segmental anatomy of the liver, triple-phase CT and imaging of hepatocellular carcinoma	3×	Vol III, p. 42
191. LI-RADS — categories, major and ancillary features, settings of use and role in management	3×	Vol III, p. 46
197. Budd–Chiari syndrome — causes, imaging, Doppler and interventional management	3×	Vol III, p. 70
206. Neonatal cholestasis and biliary atresia — US, MRI and scintigraphy	3×	Vol III, p. 102
207. Acute pancreatitis — radiography, CT and MRI	3×	Vol III, p. 108
208. Groove pancreatitis and mass-forming pancreatitis vs pancreatic adenocarcinoma	3×	Vol III, p. 111
210. Cystic pancreatic neoplasms — classification, imaging and side-branch IPMN	3×	Vol III, p. 121
216. Bosniak classification of renal cysts (version 2019) — criteria, significance and drawbacks	3×	Vol III, p. 146
217. Renal transplant — donor work-up, graft dysfunction and complications on US, Doppler and scintigraphy	3×	Vol III, p. 150
223. Carcinoma bladder — TNM/T staging with diagram, multiparametric MRI and VI-RADS	3×	Vol III, p. 175

228. Erectile dysfunction — penile Doppler technique, findings and limitations	3×	Vol III, p. 202
241. Placenta accreta spectrum and placental variants — US and MRI	3×	Vol III, p. 261
246. Acute pelvic pain in a young woman and ovarian torsion — causes and imaging	3×	Vol III, p. 285
249. Postmenopausal bleeding and endometrial carcinoma — imaging, differential diagnosis and staging	3×	Vol III, p. 301
260. Subarachnoid haemorrhage — causes, subarachnoid spaces, imaging evaluation and endovascular treatment of aneurysm	3×	Vol IV, p. 14
277. Epilepsy imaging — protocol, mesial temporal sclerosis, advanced MR and nuclear techniques	3×	Vol IV, p. 83
300. Sensorineural hearing loss in a child — inner ear anatomy and imaging work-up	3×	Vol IV, p. 177
314. Thyroid nodule — ultrasound evaluation and TI-RADS	3×	Vol IV, p. 229
325. Hyperparathyroidism — types, skeletal radiography, renal osteodystrophy and primary vs secondary	3×	Vol IV, p. 279
327. Rickets and osteomalacia — radiographic features	3×	Vol IV, p. 290
342. Cartilage imaging techniques and osteochondral lesions	3×	Vol IV, p. 342

PART 12

Chest — lungs, airways, pleura, mediastinum and diaphragm

101. Bronchopulmonary segments; hilum overlay, hilum convergence and cervicothoracic signs

ASKED 2× · 10-mark answer

Asked in: Jun 2020 · Paper II · Q3 (10 marks) · Jun 2021 · Paper II · Q1 (10 marks)

Q: a) Hilum overlay sign and its significance on diagnostic radiology. b) Cervicothoracic sign and its significance on diagnostic radiology. [5+5]

Q: Describe the anatomy of bronchopulmonary segments on radiographs and CT. Discuss the hilar overlay and hilar convergence signs and their utility. [5+5]

SOURCE

CORE — Ch 1 Thoracic Imaging — §Thoracic Imaging — pr.51, 73, 81
AMP V3 — Ch 124 Basic Radiographic Pattern of Lung Diseases — §Silhouette Sign — e.4974, e.4975
AMP V3 — Ch 132 Mediastinum — §Chest Radiograph — e.5207
AMP V3 — Ch 148 Imaging of the Pericardium — §Pericardial Effusion — e.5741
GA V1 — Ch 4 The Mediastinum, Including the Pericardium — §Approach to Mediastinal Masses — pr.69
[W1] AJR — Jardin M, Remy J. Segmental bronchovascular anatomy of the lower lobes: CT analysis — 1986;147(3):457 — https://ajronline.org/doi/10.2214/ajr.147.3.457
[W2] AJR — CT identification of bronchopulmonary segments: 50 normal subjects — 1984;142(1):47 — https://www.ajronline.org/doi/10.2214/ajr.142.1.47

Hilum overlay sign and its significance

- **Definition:** on a frontal radiograph, the hilar vessels are seen through a mass.
- **Mechanism:** a lesion lying within the hilum is obscured by the proximal pulmonary artery and looks inseparable from hilar structures.
- Hilar vessels that are clearly seen through an opacity mean the lesion lies anterior or posterior to the hilum.
- The sign was described by Felson.
- **Significance:** it shows that a mediastinal mass is present and cannot be in the middle (visceral) mediastinum.
- The mass is more likely anterior but may be posterior.
- **Anterior mass:** hilum overlay plus preserved posterior mediastinal lines identifies an anterior mediastinal mass.
  - On the lateral view, obliteration of the retrosternal clear space is a direct sign of a prevascular location.
  - Example: a right mediastinal teratoma silhouetting the right heart border, with the right pulmonary artery visible through it.
- **Posterior mass:** a schwannoma showed the sign on the frontal film, with a paravertebral abnormality on the lateral.
  - Posterior masses have sharp margins at the lung interface; anterior masses do not.
- **Bilateral hilum overlay** is described with the flask-shaped cardiac silhouette of a pericardial effusion.

FIG. 31 — AMP V3, e-book p. 4975. Hilum overlay sign in anterior mediastinal mass, the hilar vessels are seen through the lesion.

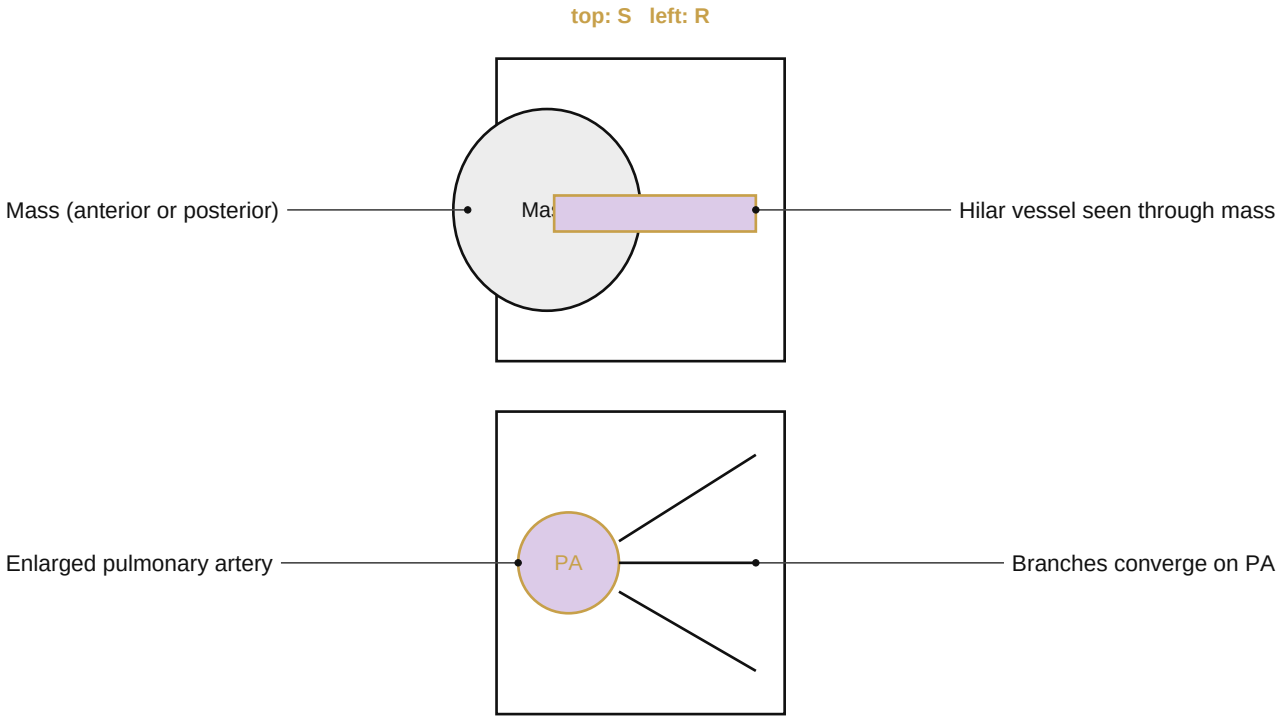

Schematic (exam diagram): Hilum overlay (top) vs hilum convergence (bottom), frontal view. *Based on CORE pr.73, pr.51; AMP V3 e.4974.*

Cervicothoracic sign and its significance

- **Use:** it separates an anterior from a posterior mass in the superior mediastinum.
- **Mechanism:** at the thoracic inlet the posterior lung extends above the clavicle.
- **Posterior mass:** it is surrounded by lung on all sides, so its margin stays sharp above the clavicle.
- **Anterior mass:** the superior margin is ill-defined because the mass is in contact with the neck soft tissues, at or below the clavicle.
- **Significance:** it narrows the differential before CT, as localising a mass within the mediastinum helps limit the differential and guide further imaging.

  - Anterior: mediastinal goitre, usually anterior and lateral to the trachea.
  - Posterior: neurogenic tumour, the most common paravertebral mass.
- Use it with the silhouette sign.
  - An anterior mass obliterates the cardiac border and ascending aorta.
  - A posterior mass obliterates the descending aorta and aortic knuckle.

Anatomy of bronchopulmonary segments on radiographs and CT

Radiograph

- Segments are not outlined on a plain film. The lobe is inferred from the contour that is lost (**silhouette sign**).
- The sign arises when juxtaposed borders have similar density.
- Left lung:
  - Aortic arch lost: left upper lobe.
  - Left heart border lost: lingula.
  - Left hemidiaphragm or descending aorta lost: left lower lobe.

FIG. 30 — AMP V3, e-book p. 4974. "Silhouette sign"—right middle lobe consolidation obscuring the right cardiac border.

Table 1: Right-lung segments (Boyden numbering) and the frontal-film border lost

Lobe	Segments	Border obscured
Right upper	Apical S1, anterior S2, posterior S3	Right superior mediastinum (SVC)
Right middle	Lateral S4, medial S5	Right heart border
Right lower	Superior S6, medial basal S7, anterior basal S8, lateral basal S9, posterior basal S10	Right hemidiaphragm

CT

- CT identified 70% of segmental bronchi and 76% of segmental arteries in 50 normal subjects. Seventy percent of the segmental bronchi and 76% of the segmental arteries were identified.
- Arteries could be traced to sixth- and seventh-order branches. Their orientation to the CT plane allowed localisation of over 75% of segments. Arteries could be traced to their sixth- and seventh-order branches
- **Right upper lobe:** the anterior and posterior segmental bronchi and vessels lie in the slice plane and are seen in long section. Long axes of origins of right upper lobe anterior and posterior segmental bronchi and vessels lie in plane of CT

slice

- The apical segmental bronchi lie perpendicular to the plane. long axes of apical segmental bronchi lie perpendicular to plane
- **Right lower lobe:** medial basal segment vessels are perpendicular to the slice and cut transversely.
- Anterior, lateral and posterior basal vessels are obliquely sectioned.
- The inferior accessory fissure can define the limits of the medial basal segment.
- **Lower-lobe relations:** segmental arteries lie toward the periphery relative to their bronchi, and segmental veins lie central to them. arteries generally lie toward the lung periphery relative to their corresponding bronchi... veins generally lie central
- **Pitfalls:** the lingular bronchi (LB4, LB5) are the hardest to identify because of obliquity and cardiac streak artefact.
- Lower-lobe variation from the dominant pattern occurs in up to 20% of cases. variation from the dominant pattern occurred in as many as 20% of cases
- Segmental arteries may be single, duplicate or triplicate.

Hilum convergence sign and its utility

- **Definition:** hilar pulmonary artery branches converge into an enlarged pulmonary artery.
- The vessels converge on the lateral aspect of the hilum, and the hilar angle keeps its normal concave shape.
- **Utility 1:** it confirms that an apparent mediastinal "mass" is the pulmonary artery.
- **Utility 2:** it points to vascular dilatation as the cause of hilar enlargement.
- **Utility 3:** a main pulmonary artery diameter ≥2.9 cm, or larger than the aortic root, suggests pulmonary hypertension. This is neither highly sensitive nor specific.
- Pulmonary artery wall calcification is pathognomonic for chronic pulmonary artery hypertension, typically from shunts.
- Pulmonary hypertension may cause mosaic attenuation, most often in chronic thromboembolic pulmonary hypertension (CTEPH).

Table 2: Hilum overlay vs hilum convergence sign

Feature	Hilum overlay	Hilum convergence
Finding	Hilar vessels seen through the opacity	Branches converge into an enlarged pulmonary artery
Meaning	True mediastinal mass, not middle mediastinum	Vascular enlargement, not a mass
Utility	Localises the mass: anterior (more likely) or posterior	Excludes a mass; suggests pulmonary hypertension

PEARLS

- **Hilum overlay:** hilar vessels are visible through a mass, so the mass is not in the middle mediastinum. It is usually anterior and sometimes posterior.
- **Hilum convergence:** vessels converge into an enlarged pulmonary artery, which mimics a mediastinal mass. It is not a mass.
- **Cervicothoracic sign:** a margin that stays sharp above the clavicle means posterior. An ill-defined margin at or below the clavicle means anterior.
- **Silhouette sign:** the lost contour gives the lobe. Right heart border is the right middle lobe, and left heart border is the lingula.
- **Trap:** a main pulmonary artery ≥2.9 cm is neither sensitive nor specific for pulmonary hypertension.
- On CT, segments are localised by the segmental artery and bronchus. The arteries lie peripheral to the bronchi in the lower lobes.

102. Chest radiograph views — technique and indications of any five

ASKED 1× · 10-mark answer

Asked in: Dec 2021 · Paper II · Q6 (10 marks)

Q: Discuss in brief, the technique and indication, of any five 'views' while doing a X-ray chest. [2+2+2+2+2]

SOURCE

GA V1 — Ch 1 Current Status of Thoracic Imaging — §Radiographic Projections — p. 3
GA V1 — Ch 3 The Chest Wall, Pleura, Diaphragm and Intervention — §Free pleural fluid; §Atypical Signs — pp. 44, 51
AMP V3 — Ch 122 Chest Radiography and Sonography: Techniques and Anatomy — §Special Radiographic Techniques — e.4868
AMP V3 — Ch 127 Nontubercular Pulmonary Infections — §Fungal Infections — e.5085
AMP V3 — Ch 138 Imaging of Pleura — §Imaging in Pleural Effusion — e.5458

Frontal (PA) and lateral views

- **Technique:** these are the standard pair. Frontal and lateral projections are adequate for most purposes.
- **Indication:** first-line study for almost all chest problems.
- **Digital receivers:** computed radiography (CR) uses a photostimulable phosphor plate. Direct radiography (DR) uses flat-panel detectors with direct or indirect conversion. Both have wider latitude, which lowers error and repeat rates.
- **Lateral view:** localises a lesion seen on the frontal film, and a subpulmonic effusion is suspected from the erect PA and lateral pair together.
- **Other views:** lordotic, expiratory and portable lateral shoot-through views are now usually done only when CT is not readily available.

Lateral decubitus view

- **Technique:**
  - It is a frontal projection with a horizontal beam, with the patient lying on one side.
  - It is also called the cross-table lateral decubitus view.
  - The dependent hemidiaphragm normally rises considerably in this view.
- **Pleural effusion:**
  - It shows an effusion not visible on the erect film, and shows fluid moving in the pleural space.
  - Fluid moves with gravity and the lung floats on it, which raises sensitivity.
  - As little as 10 mL can be seen on a decubitus film. At least 175 mL is needed to blunt the costophrenic angle on an erect frontal film.
  - Ultrasound is often easier for small effusions, and most institutions no longer perform decubitus films.
- **Equivocal opacity:** it localises or confirms an equivocal opacity seen on the frontal film.
- **Mobile intracavitary lesion:**
  - It shows the mobility of a **fungus ball** (aspergilloma) within a cavity.
  - The fungus ball lies in the dependent part of the cavity.
  - A fungus ball is typically seen with an **air crescent sign**.
- **Pneumothorax in a patient who cannot stand:**
  - The patient can have a lateral decubitus view, or a supine decubitus projection.
  - For the supine projection the cassette is placed dorsolaterally at 45 degrees, and the x-ray tube is angled perpendicular to the cassette.
  - It also demonstrates small pneumothoraces.

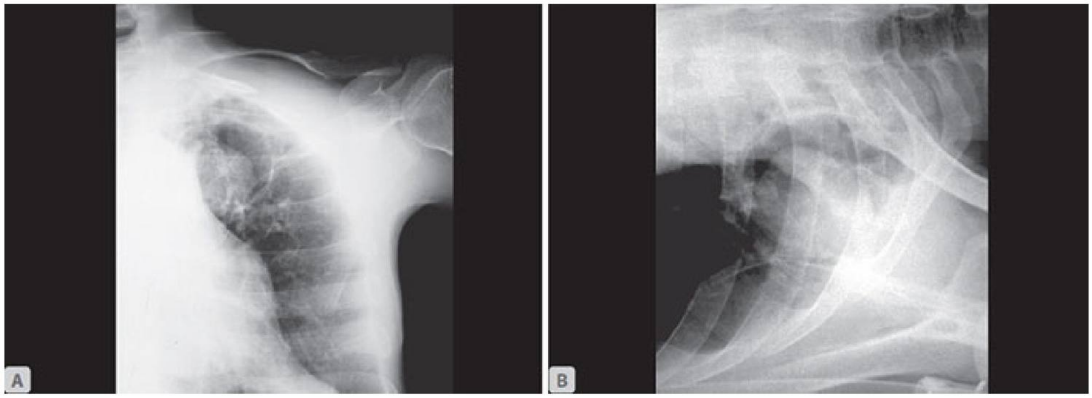

FIGS. 26A AND B *— AMP V3, e-book p. 5085. FIGS. 26A AND B: Frontal chest radiograph (A) shows a cavity containing an intracavitary fungus ball with a crescent of air above the mycetoma. Lateral decubitus view (B) shows the fungus ball lying in the dependant part of cavity suggesting movement of the mycetoma within the cavity.*

- **Supine pneumothorax signs** (from the supine film itself):
  - In the supine position, pleural air collects anteriorly, particularly medially and basally.
  - Signs are ipsilateral transradiancy, a deep finger-like lateral costophrenic sulcus, and a double diaphragm sign.

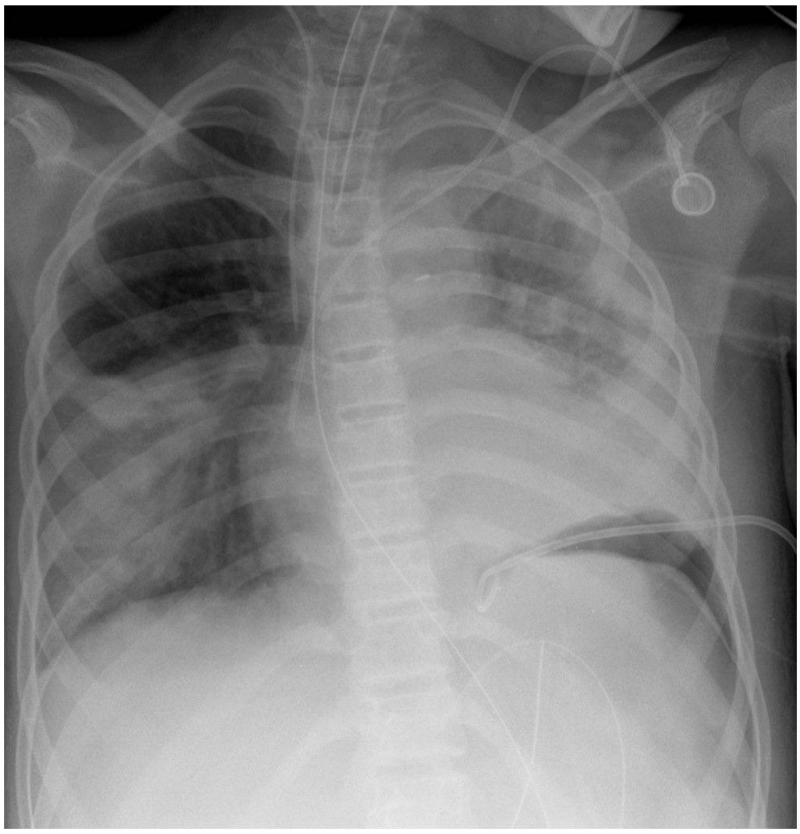

Fig. 3.19 *— GA V1, p. 51. Supine Pneumothorax. Portable chest radiograph after development of a pneumothorax in a patient with a bilateral pneumonia. There is an increase of transradiancy at the left lung base and the costophrenic sulcus laterally is more pronounced ('deep sulcus sign').*

Lordotic view

- **Technique:**
  - The patient leans backward in a lordotic position, or more commonly the x-ray tube is tilted cranially.
  - The clavicles are projected above the lung fields.
  - Anterior and posterior parts of the ribs usually overlap.
  - The lower chest is highly distorted.
- **Indications:**
  - Clear demonstration of the **lung apices**.
  - Confirming middle lobe and lingular abnormalities.
- **Today:** it is mainly used when CT is not readily available.

Oblique view

- **Technique:**
  - Right or left posterior oblique views are taken.
  - The degree of obliquity is best determined with fluoroscopy.
- **Indications:**
  - It is preferred to the lateral view in bilateral disease, because it reduces superimposition of the two lungs.
  - The left oblique view is particularly useful for demonstrating the trachea and its divisions.

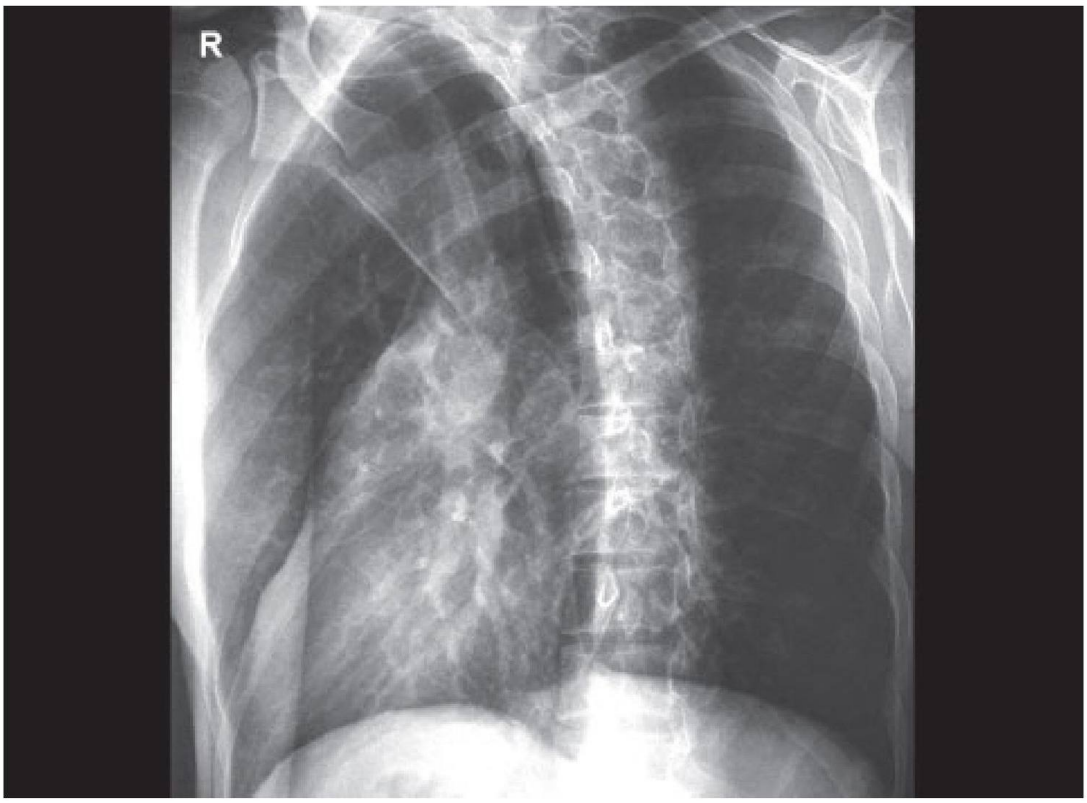

FIG. 5 — AMP V3, e-book p. 4868. Right oblique view of normal chest.

Inspiratory–expiratory (expiratory) view

- **Technique:**
  - Radiographs are exposed at full inspiration and at maximal expiration, and then compared.
  - To show air trapping convincingly, expiration must be forced.
- **Indication 1: air trapping**
  - **Generalised:** asthma or emphysema. Diaphragmatic excursion is reduced symmetrically, and lung density changes little between the two films.
  - **Local air trapping.**
- **Indication 2: suspected pneumothorax**
  - In doubtful cases a repeat film, an expiratory film or a decubitus film may clarify the situation.
  - If doubt remains, CT distinguishes bullae from pneumothorax.

Table 1: Views compared — what each adds to the standard frontal film

View	Main question answered	Detection or finding	Limit
Lateral decubitus	Free vs loculated fluid; small pneumothorax	Effusion ≈10 mL	Ultrasound often easier
Lordotic	Apical or middle lobe/lingular lesion	Clavicles projected above lungs	Lower chest distorted
Oblique	Bilateral disease; tracheal divisions	Less superimposition of lungs	Obliquity set by fluoroscopy
Inspiratory–expiratory	Air trapping; pneumothorax	Little density change in trapping	Expiration must be forced
Frontal and lateral	Routine survey	Adequate for most purposes	Subpulmonic fluid may be missed

PEARLS

- Standard chest examination is a frontal plus lateral pair; the other views answer a specific question.
- Lateral decubitus (horizontal beam, patient on side) is the most sensitive plain-film view for small effusion, about 10 mL.
- Lordotic view (cranial tube tilt) shows the apices and middle lobe/lingula, with the clavicles above the lung fields.
- Oblique view is preferred to the lateral in bilateral disease, and the left oblique shows the trachea and its divisions.
- Forced expiratory film is for air trapping (asthma, emphysema); the lung changes little in density and the diaphragm moves little.
- Supine pneumothorax: look for the deep sulcus sign, then confirm with a decubitus film or CT.
- Exam trap: lordotic, expiratory and decubitus views are largely replaced by CT or ultrasound where these are available.

103. Calcifications on the chest radiograph — differential diagnosis

ASKED 1× · 5-mark answer

Asked in: Dec 2021 · Paper II · Q9(b) (5 marks)

Q: Discuss differential diagnosis of: Calcifications on X-ray chest. [5]

SOURCE

CHAP — Ch 5 Chest — §Pulmonary calcification or ossification; Bilateral hilar enlargement; Egg-shell calcification; Pleural calcification — pp. 84, 92, 95
CHAP — Ch 6 Cardiovascular system — §Cardiac calcification — p. 113
AMP V3 — Ch 124 Basic Radiographic Pattern of Lung Diseases — §Characteristics of the Lesion Itself — e.4969–4970
AMP V3 — Ch 133 Imaging of Solitary Pulmonary Nodule — §Internal Characteristics: Calcification — e.5260–5261, e.5263

Mechanism

- **Dystrophic calcification** is calcium deposited in dead or non-vital tissue. It is common in India in tubercular disease of the lung.
- **Metastatic calcification** occurs in otherwise healthy lung, e.g. with hypercalcaemic states.

Causes by site

Lung – localized

- **TB** is the commonest cause, with a small nidus of calcification. Calcification does not mean the disease is healed.
- **Histoplasmosis** (endemic areas) may show laminated, target-like calcification, with or without splenic calcifications.
- **Coccidioidomycosis**, and rarely **blastomycosis**.
- **Hamartoma** shows popcorn calcification, which is virtually diagnostic of cartilage-containing tumours.

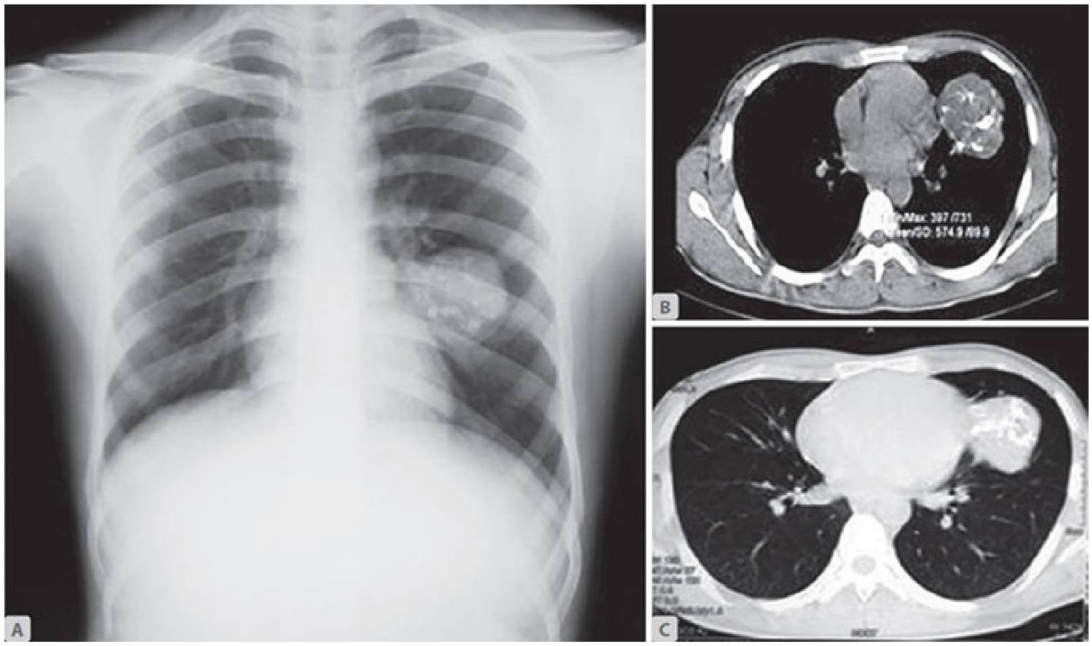

FIGS. 12A TO C — AMP V3, e-book p. 5263. FIGS. 12A TO C: Chest radiograph (A) showing a large solitary nodule in the left lung with dense nodular foci of calcification within s/o characteristic popcorn calcification/central cartilage calcification. Noncontrast CT scan mediastinal window (B) showing a 3 x 3 cm nodule containing overlapping, randomly distributed small rings of calcification or the popcorn calcification

Solitary nodule

- Calcification usually suggests a benign lesion.
- Benign patterns are target (concentric), popcorn, homogeneous and dense central (bull's eye) calcification.
- Exceptions to the benign rule:
  - Lung cancer engulfing a calcified granuloma, which gives eccentric calcification.
  - Calcifying or ossifying metastasis from osteosarcoma, chondrosarcoma, mucinous colon or breast adenocarcinoma, papillary thyroid carcinoma, ovarian cystadenocarcinoma or carcinoid.
  - Primary peripheral squamous cell carcinoma or papillary adenocarcinoma.
- Stippled or punctate calcification is indeterminate.



FIGS. 10A TO D — AMP V3, e-book p. 5261. FIGS. 10A TO D: Calcification in benign module.

Lung – diffuse or multiple

- **Healed miliary TB, histoplasmosis or varicella pneumonia.** Varicella gives numerous 1–3 mm calcifications.
- **Chronic pulmonary venous hypertension**, especially mitral stenosis. Nodules are up to 8 mm, with or without ossification, and are most prominent in the mid and lower zones.
- **Silicosis** shows calcification in up to 20% of those with nodular opacities.
- **Metastases** (as above).
- **Alveolar microlithiasis** is often familial. Myriad minute calcifications obscure lung detail, and the heart, pleura and diaphragm may appear as negative shadows.
- **Metastatic calcification** from hypercalcaemia (chronic renal failure, secondary hyperparathyroidism, myeloma). It is predominantly in the upper zones.

Lymph nodes

- **Egg-shell calcification** is a shell-like peripheral calcification <2 mm thick in ≥2 nodes. At least one ring must be complete, and one node must be ≥1 cm.
  - **Silicosis**: seen in ~5%, mainly in hilar nodes.
  - **Coal worker's pneumoconiosis**: seen in only 1%.
- Irregular nodal calcification is frequent in healing or healed TB.

Pleura

- **Asbestos** causes plaques adjacent to the anterior rib ends and over the diaphragm, usually bilateral.
- **Prior infection** (TB pleuritis or empyema) gives a large unilateral calcified plaque.
- **Talc pleurodesis**: the calcified thickening can stay PET-avid for years and should not be mistaken for malignancy.
- **Prior haemothorax** may leave a calcified haematoma.

Heart, vessels and airway

- **Valves** (visible on CXR, so suggests significant stenosis):
  - Aortic: bicuspid valve (a ring with a central bar), degenerative sclerosis or rheumatic fever.
  - Mitral: degenerative annular (J-shaped) or rheumatic (leaflets, amorphous or nodular).
- **Intracardiac**: calcified LV or LA appendage thrombus (thick, laminated), papillary muscle calcification, and calcified myxoma.
- **Main pulmonary artery wall** may calcify in chronic pulmonary arterial hypertension.
- **Tracheobronchial tree**: physiological in the elderly, more often in women. In the young it suggests hypercalcaemia.
- **Costal cartilage** calcification is common and normal.

Discriminating features

Table 1: Calcification patterns on chest radiograph

Pattern	Cause	Key feature
Popcorn	Hamartoma	Cartilage-containing tumour
Concentric / uniform	TB or fungal granuloma	Benign nodule
Eccentric	Cancer engulfing a granuloma	Indeterminate or malignant
1–3 mm, numerous	Varicella	Healed pneumonia
Mid/lower zone, ≤8 mm	Mitral stenosis	May ossify
Upper zone	Hypercalcaemia	Metastatic calcification
Complete thin shell	Silicosis, coal worker's pneumoconiosis	Nodes ≥1 cm
Rib ends, diaphragm	Asbestos	Bilateral pleural plaques

PEARLS

- A calcified solitary nodule is usually benign, but eccentric calcification and calcifying metastases are the exceptions.
- Popcorn calcification points to a hamartoma. Laminated or target calcification points to a granuloma.
- Egg-shell nodal calcification suggests silicosis or coal worker's pneumoconiosis.
- Pleural plaques at the rib ends and diaphragm suggest asbestos. A large unilateral calcified plaque suggests old TB or empyema.
- Calcified talc pleurodesis can remain PET-avid and should not be mistaken for tumour.
- Exam trap: calcification on CXR does not prove a TB lesion is healed.

104. ICU chest radiograph — tubes, lines and catheters

ASKED 1× · 10-mark answer

Asked in: Jun 2020 · Paper II · Q10 (10 marks)

Q: Discuss the imaging evaluation of various catheters, tubes and lines seen on a chest radiograph in an ICU setting. [10]

SOURCE

GA V1 — Ch 10 Thoracic Trauma and Related Topics — §Pneumonia; §Intravascular (airway, intravascular lines, Table 10.3) — pp. 240, 243
GA V1 — Ch 13 Congenital Heart Disease — Fig. 13.2 — pp. 293–294
AMP V3 — Ch 136 Intensive Care Chest Radiology — e.5407, e.5419, e.5420
AMP V3 — Ch 122 Chest Radiography and Sonography — e.4870

Approach to the ICU chest radiograph

- Most ICU films are portable AP radiographs. They are usually taken supine, and technique varies from day to day.
- Obtain a film after insertion of an endotracheal tube, central venous line, chest tube or intra-aortic balloon.
- ACR indications for portable films are placement of enteric tubes, endotracheal tubes, central venous catheters, Swan–Ganz catheters, other life-support devices, or a change in clinical status. Routine daily films are not advised.
- Name every device, trace it from entry to tip, and compare the tip with its ideal position (Table 1).
- Then look for complications of placement: pneumothorax, pneumomediastinum, effusion, collapse, haematoma.
- Identify each line and tube and its tip position. The tubes and lines on one ICU film are shown in.

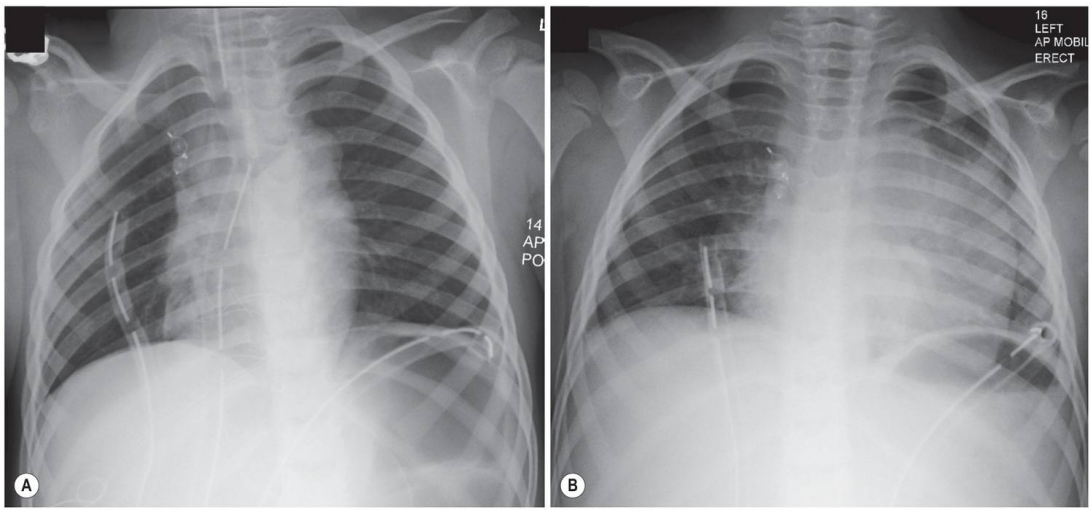

Fig. 13.2 *— GA V1, p. 294. Perioperative Chest X-Ray. (A) A 3-year-old patient following total cavo-pulmonary connection surgery, postoperative chest x-ray demonstrating tube positions in intensive care. Note two chest and one mediastinal drains, endotracheal tube and veno-venous collateral occluder device (right upper zone). (B) Third postoperative day following extubation and removal of mediastinal dra*

Table 1: Tubes, lines and catheters on an ICU chest radiograph

Device	Ideal tip position	Malposition / complication to look for
Endotracheal tube	Mid-trachea, about 5 cm above carina in adults; table range 3–8 cm	Too low: right main bronchus, then left lung collapse. Too high: extubation, laryngeal injury
Tracheostomy tube	Between half and two-thirds of the stoma–carina distance; cuff fills but does not distend the trachea	Over-distended cuff: tracheal injury; pneumomediastinum
Central venous catheter	Medial end of first rib at brachiocephalic–SVC junction, or within SVC	Above clavicle: subclavian artery. In atrium: arrhythmia, perforation
PICC	Within SVC	As for central venous catheter
Swan–Ganz catheter	Right or left pulmonary artery	Beyond proximal interlobar arteries: infarction
Left atrial catheter	Left atrium	—
Pleural (chest) tube	Mid-axillary line, 6th–8th spaces; anterior for pneumothorax, posterior for effusion	Side holes outside pleura; intraparenchymal tube causes contusion
Mediastinal drain	Anterior mediastinum or posterior pericardium	—
Temporary pacing wires	Over right heart	—
Nasogastric tube	Left upper quadrant, side holes in stomach	Disrupts oesophagogastric sphincter, so aspiration

Airway devices

Endotracheal tube

- The ideal tip lies mid-trachea, about 5 cm above the carina in an adult. This allows for movement when the head moves.
- Neck flexion or extension can shift the tip about 2 cm caudally or cranially.
- A tube that is too low usually enters the right main bronchus. This causes impaired ventilation and ultimately left lung collapse.
  - Look for contralateral atelectasis, ipsilateral hyperinflation and barotrauma.
  - After repositioning, re-expansion may take hours to days.
- A tube that is too high risks accidental extubation or laryngeal damage.
- The cuff must not be inflated beyond the tracheal diameter, as this risks rupture or later tracheal stenosis.
- Oesophageal intubation is usually clinically apparent and fills the GI tract with air.

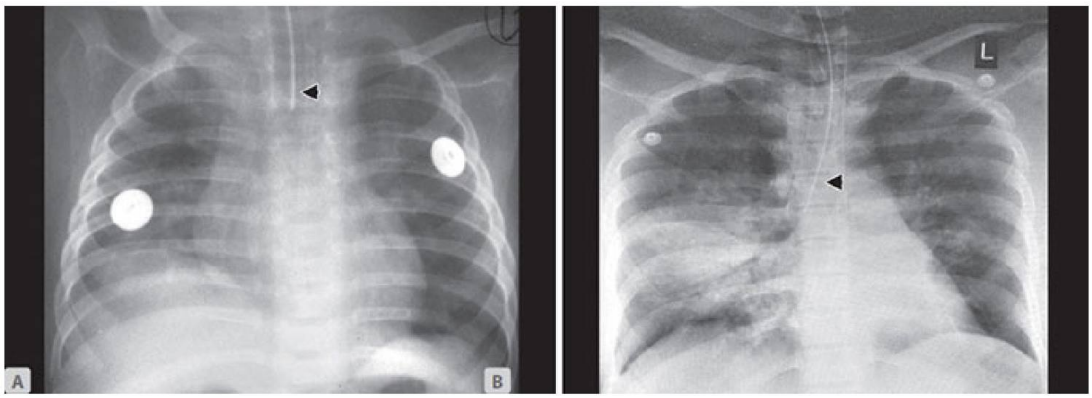

***FIGS. 9A AND B** — AMP V3, e-book p. 5420. FIGS. 9A AND B: Endotracheal tube position: Chest radiographs showing (A) correct and (B) abnormal (right bronchial) positions of the endotracheal tube (arrowheads).*

Tracheostomy tube

- Used for long-term ventilation. It is not displaced by head movement.
- The tip lies between half and two-thirds of the way from stoma to carina.
- Tip at about T3, and tube diameter about two-thirds of the tracheal diameter.
- Pneumomediastinum may follow even an uncomplicated placement.

Intravascular lines

Central venous catheter and PICC

- The tip should project between the medial end of the first rib (brachiocephalic–SVC junction) and the SVC itself.
- The tip should lie beyond the venous valves. A lower SVC or cavoatrial tip carries less thrombosis risk. It must not lie within the atrium.
- A catheter tip above the clavicle on an AP film should raise suspicion of subclavian artery placement. Colour of blood may mislead in sepsis or hypotension.
- Complications on the film:
  - **Pneumothorax**, especially after subclavian puncture.
  - **Mediastinal widening** from venous laceration or extravenous insertion.
  - Rapidly developing pleural effusion.

Swan–Ganz (pulmonary artery) catheter

- It enters the pulmonary artery about 5 cm beyond the main pulmonary artery bifurcation. The balloon is then inflated to wedge it.
- In use, it must not extend beyond the proximal interlobar arteries. More distal placement increases the risk of **pulmonary infarction**.

Other devices

- Intra-aortic balloon counterpulsation devices, transvenous and epicardial pacing wires, thoracostomy tubes and nasogastric tubes may also be seen.
- Postoperative cardiac films are needed to locate catheters, chest drains and endotracheal tubes.

Pleural tubes

- The tube enters via the mid-axillary line at the 6th–8th rib spaces. It is directed anteriorly for pneumothorax and posteriorly for effusion.
- About 10% are malpositioned.
- All side holes must lie within the pleural space. They are seen as interruptions of the radiopaque line.
- A tube in the lung causes contusion, seen as a new opacity beside the tube on radiograph or CT.
- A malpositioned tube may injure the heart, great vessels, diaphragm or upper abdominal organs.

Nasogastric tube

- The tip should lie in the left upper quadrant with the side holes in the stomach.
- An NG tube disrupts the oesophagogastric sphincter and predisposes to aspiration.

Complications to exclude after line placement

- **Pneumothorax** on a supine AP film often lacks the classic lung edge. Air collects anteriorly.
  - Look for unusually sharp heart border or SVC outline.
  - Look for the **deep sulcus sign**.
  - With a subpulmonary pneumothorax there is a hyperlucent upper abdomen and a sharply demarcated diaphragm.
  - Ultrasound shows absent lung sliding and absent comet-tail artefact. It is more sensitive than radiography and as sensitive as CT.
- **Pneumomediastinum** shows linear mediastinal air streaks.
  - Signs are the ring around the pulmonary artery, the **double bronchial wall sign**, and the **continuous diaphragm sign**.
- **Pneumopericardium** shows air outlining the superior pericardial reflection around the great vessels, with the main pulmonary artery visible.
- Pleural effusion: in a supine patient, free fluid layers posterobasally and gives a diffuse hazy increase in density. Ultrasound or CT can confirm it.
- Atelectasis or collapse from a deep ETT, as above.

PEARLS

- Check every tube and line from entry to tip on every ICU film.
- ETT tip is about 5 cm above the carina (GA table range 3–8 cm). A deep tube goes into the right main bronchus and collapses the left lung.
- Central line tip should lie at the brachiocephalic–SVC junction or in the SVC, not in the atrium.
- A tip above the clavicle on an AP film suggests arterial placement.
- Swan–Ganz tip must stay proximal to the interlobar arteries, or infarction results.
- After line insertion, look for pneumothorax (**deep sulcus sign**, sharp heart border), pneumomediastinum and widened mediastinum.
- All chest-tube side holes must lie within the pleural space.

105. Lobar collapse — types, general signs and localising signs

ASKED 1× · 10-mark answer

Asked in: Jun 2020 · Paper II · Q5 (10 marks)

Q: Describe various types of lung collapse. Discuss radiologic features of collapse in general and the specific imaging features which help in localization of collapse. [4+6]

SOURCE

GA V1 — Ch 7 Pulmonary Lobar Collapse: Essential Considerations — §Radiographic Considerations to Combinations of Lobar Collapse — pp. 163–177

Types of lung collapse

- **Collapse/atelectasis** means loss of volume within the lung. North American usage often reserves "collapse" for complete loss of volume of a whole lobe or lung.
- Collapse is classified by extent and by aetiology (Table 1).

Table 1: Types of collapse by extent and mechanism

Basis	Type	Key points
Extent	Linear, plate-like, subsegmental	Smallest volume loss
Extent	Sublobar, lobar, whole lung	Segmental, lobar or "white-out" of a hemithorax
Mechanism	**Obstructive (post-stenotic)**	Endobronchial or extrinsic obstruction
Mechanism	**Compression (passive)**	Pleural effusion, pneumothorax or bulla
Mechanism	**Rounded atelectasis**	Sublobar; follows a previous, often haemorrhagic, exudative effusion (post-thoracotomy, trauma, asbestos); adjacent visceral pleural thickening
Mechanism	Others without obstruction	Radiation-induced collapse; tumour replacement (adenocarcinoma)

Causes of obstructive collapse

- **Intrinsic:**
  - Bronchogenic carcinoma, carcinoid, adenoid cystic carcinoma, metastases and lymphoma
  - Benign tumours; sarcoidosis and tuberculosis
  - Foreign bodies, mucous plugs, gastric contents and a malpositioned endotracheal tube
- **Extrinsic:** hilar or mediastinal nodes, mediastinal masses, fibrosing mediastinitis, aortic aneurysm or vascular anomalies, and cardiac enlargement.
- **Adults:** tumours and mucous plugs are the common intrinsic causes. In a middle-aged or elderly smoker, suspect bronchogenic carcinoma until proved otherwise.
- **Children:** inhaled foreign bodies and mucous plugs are common; tumours are very rare.

General radiological features of collapse

Direct signs

- **Increased opacity** and volume loss are the cardinal features.
  - Retained secretions or fluid dominate the opacity; near-complete collapse is needed for lung to look dense through loss of air alone.
- **Fissure displacement** is a reliable sign and is characteristic for each lobe.
- **Crowding of vessels and bronchi** can be an early sign; compare with old films.
- **Hilar displacement:**
  - Hilar elevation on the PA film indicates upper lobe collapse.
  - A small hilum, with the lower lobe artery obscured, indicates lower lobe collapse.
- **Bronchial reorientation:**
  - Upper lobe collapse makes the main bronchus more horizontal.
  - Lower lobe collapse makes the main bronchus more vertical.

Indirect signs

- **Compensatory hyperinflation:**
  - The adjacent lobes show fewer, widely spaced vessels.
  - With large volume loss the contralateral lung crosses the midline and displaces the anterior junctional line.
  - The lateral view shows a hyperlucent anterior mediastinum.
- **Mediastinal shift:**
  - It is least in right middle lobe collapse and greatest, especially inferiorly, in lower lobe collapse.
  - Acute upper lobe collapse shows little shift; chronic collapse with fibrosis shows more.
  - The trachea is a useful marker of superior mediastinal shift.
- **Hemidiaphragm elevation** is of limited value because the right hemidiaphragm normally lies 0–3 cm higher than the left.
- **Juxtaphrenic peak:** a small triangular density at the dome of the hemidiaphragm. It occurs in upper lobe collapse, or right upper plus middle lobe collapse, and is due to traction on an inferior accessory fissure.
- **Rib crowding** is seen in chronic collapse and is unreliable because rotation or scoliosis can mimic it.
- **Shifting granuloma sign:** a parenchymal lesion changes position as the lobe collapses.
- **Luftsichel sign** ("air crescent"):
  - The sign is paramediastinal lucency from the overinflated superior segment of the lower lobe interposed beside the collapsed upper lobe.
  - It is typical of left upper lobe collapse.

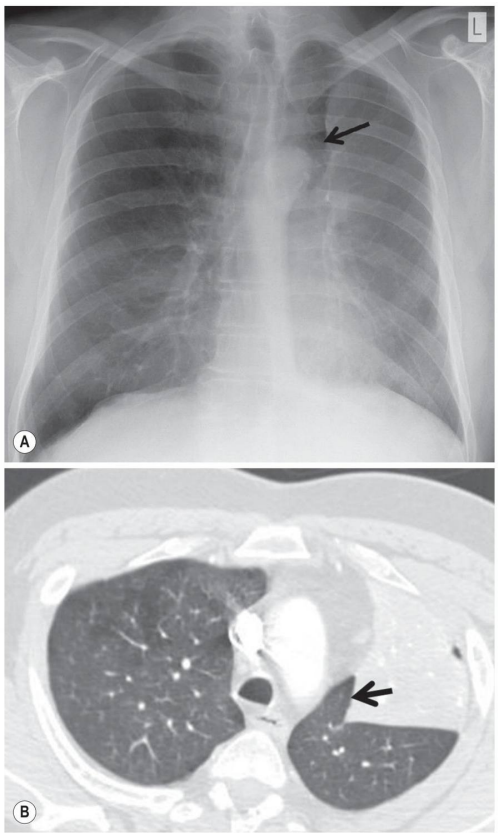

Fig. 7.4 — GA V1, p. 166. Luftsichel Sign. (A) A left upper lobe collapse demonstrating paramediastinal lucency (arrow). (B) Computed tomography shows interposition of aerated lung between the collapse and the aortic arch (arrow).

Signs of a central obstructing mass

- **Golden's S sign:**
  - The fissure shows peripheral concavity and central convexity, forming a reverse S on the right, due to a central mass.
  - It was described in the right upper lobe but can occur in any lobe.
- **Absent air bronchograms** favour a central obstructing mass rather than pneumonia.
  - Exceptions are partial obstruction and bronchopneumonia with exudate-filled airways.

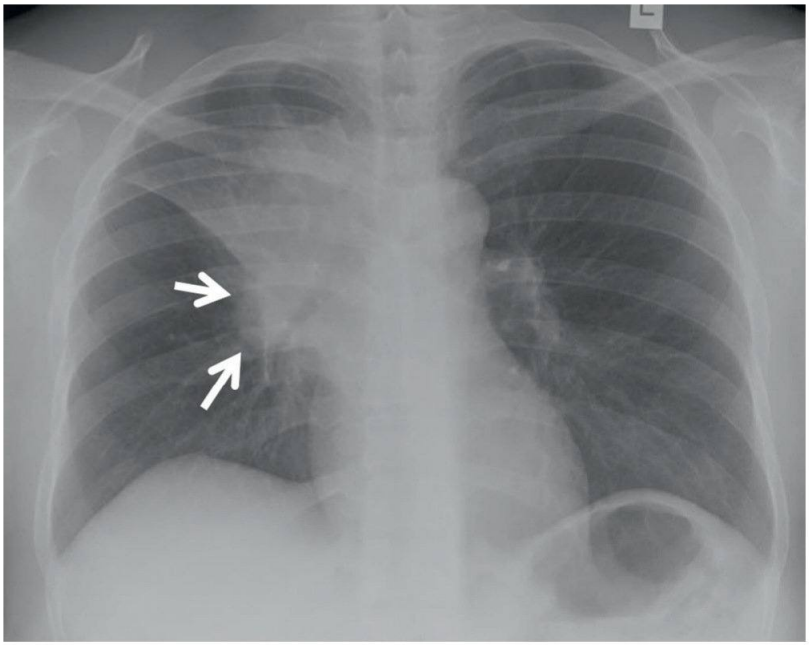

Fig. 7.6 — GA V1, p. 167. Golden's S Sign. A right upper lobe collapse demonstrating peripheral concavity and central convexity (arrows) due to an underlying bronchogenic carcinoma resulting in a reverse S shape.

CT features

- CT avoids superimposition and gives multiplanar views. Reported sensitivity for detecting an obstructing carcinoma is 83–100%.
- **Enhancement:**
  - Collapsed lung enhances more than tumour.
  - The difference is maximal 40 s to 2 min after the contrast bolus.
  - Atelectatic lung enhances strongly and homogeneously; consolidation enhances poorly.
- **CT S sign:** a localised convexity of the fissure indicates a mass. It applies to all lobes on CT.
- **CT mucous bronchogram sign:**
  - Low-attenuation, branching tubular airways lie within the enhancing collapsed lobe.
  - Causes are obstructing carcinoma, tuberculous bronchostenosis, ABPA, asthma and cystic fibrosis.
- **Air bronchograms on CT** do not exclude a central lesion; collateral air drift or necrosis can produce them.
- **Drowned lobe:** a fluid-filled, sometimes expanded, lobe with little volume loss.
- **Pitfall:** a left lower lobe draped over the descending aorta can mimic a mass.
- Acute collapse may show apparent bronchiectasis that later resolves.

Other modalities

- **MRI:** inferior to CT. On T2, tumour has lower signal than obstructed lung.
- **Ultrasound:** collapsed lung in a large effusion appears as a hyperechoic wedge in anechoic fluid.
- **PET/CT:** collapsed lung takes up less FDG than tumour, which helps in biopsy and radiotherapy planning.

Localising features of individual collapses

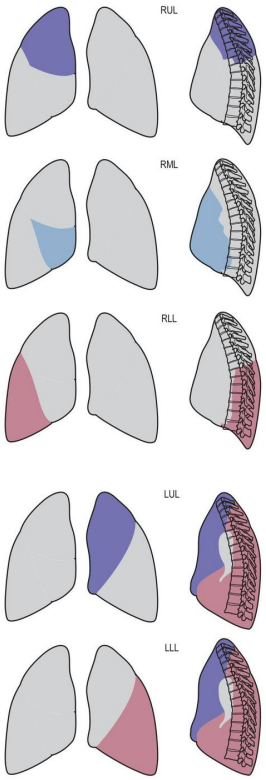

Fig. 7.30 *— GA V1, p. 177. Schematic Appearances of the Various Lobar Collapses on Frontal and Lateral Radiographs. LLL, Left lower lobe; LUL, left upper lobe; RLL, right lower lobe; RML, right middle lobe; RUL, right upper lobe.*

CLINICA
PUBLICATION

DNB EXIT EXAM · SOLVED PREVIOUS-YEAR QUESTION PAPERS

DNB Radiodiagnosis

Solved Previous-Year Questions

VOLUME III

Body Trauma, Liver, Biliary and Pancreas, Genitourinary, Obstetrics and Gynaecology

Answers are written from six radiology textbooks — Grainger & Allison 7e, Rumack & Levine 6e, Chapman & Nakielny 7e, Christensen 4e, AIIMS-MAMC-PGI 3e and Core Radiology 2e — one lead book per question, with the chapter and pages named in each answer, and from current reporting systems, guidelines and Indian regulations found on official sites, listed in the Web-Sourced Facts Register.

REVIEWED BY

Dr Hemant Kumar
DNB Radiodiagnosis

Dr. Khusbo Singh
DNB Radiodiagnosis

UPDATED TILL OCTOBER 2026

CLINICA PUBLICATION
www.clinicapublication.com

Index

HOW TO USE

Each answer groups every year and paper the question was asked in and is written to the union of what those versions asked. The badge shows how often it was asked. The SOURCE box under each question names the textbook chapters and pages used and any current guideline or web source [W#]; every [W#] is also listed in the register at the end. Book images carry their own figure number and page; anatomy and diagram questions also carry a schematic exam diagram you can reproduce in 2–3 minutes. A lists the parts, B this volume question by question, C the high-yield topics (asked 3× or more).

A · Parts

Part 15 — Body trauma	8 answers	9
Part 16 — Liver, biliary system and pancreas	24 answers	42
Part 17 — Genitourinary, adrenal and male reproductive	19 answers	140
Part 18 — Obstetrics and fetal imaging	13 answers	225
Part 19 — Gynaecology and the female pelvis	13 answers	285

B · This volume, question by question

182. Abdominal trauma — imaging approach and FAST, including extended FAST in chest trauma Asked in: Jun 2021 · Paper II · Q4(a) (5 marks) · Dec 2022 · Paper II · Q1 (10 marks)	2×	9
183. Splenic trauma — imaging findings and AAST grading Asked in: Jun 2021 · Paper II · Q4(b) (5 marks) · Jun 2025 · Paper II · Q10 (10 marks)	2×	12
184. Liver injury — AAST scale and delayed complications Asked in: Oct 2023 · Paper II · Q10 (10 marks)	1×	15
185. Traumatic visceral vascular injuries — imaging and interventional radiology Asked in: Oct 2024 · Paper II · Q9 (10 marks)	1×	18
186. Renal trauma and haematuria after blunt trauma — approach, imaging and grading Asked in: Dec 2020 · Paper III · Q10 (10 marks) · Dec 2022 · Paper II · Q5 (10 marks)	2×	23
187. Male urethral trauma — imaging (draw and discuss) Asked in: Dec 2021 · Paper III · Q2(b) (5 marks)	1×	28
188. Urinary bladder trauma — types and imaging including extraperitoneal rupture Asked in: Apr 2023 · Paper II · Q10 (10 marks) · Dec 2025 · Paper II · Q10(a) (5 marks)	2×	32
189. Pelvic fractures — imaging evaluation and patterns of osseous and soft-tissue injury Asked in: Jun 2021 · Paper II · Q10 (10 marks)	1×	35
190. Segmental anatomy of the liver, triple-phase CT and imaging of hepatocellular carcinoma Asked in: Jun 2020 · Paper III · Q9 (10 marks) · Apr 2023 · Paper III · Q1 (10 marks) · Jun 2025 · Paper III · Q3(a) (3 marks)	3×	42
191. LI-RADS — categories, major and ancillary features, settings of use and role in management Asked in: Jun 2021 · Paper III · Q2 (10 marks) · Dec 2022 · Paper III · Q2 (10 marks) · Jun 2025 · Paper III · Q3(b) (7 marks)	3×	46
192. MRI of hepatocellular carcinoma after locoregional therapy and LI-RADS treatment response Asked in: Oct 2024 · Paper III · Q2 (10 marks)	1×	51
193. Hyperenhancing liver lesions on CT — differentiating features Asked in: Jun 2022 · Paper III · Q8 (10 marks)	1×	55
194. Chronic liver disease — role of imaging Asked in: Jun 2022 · Paper III · Q3 (10 marks)	1×	59
195. Hepatic fat estimation techniques and NAFLD Asked in: Oct 2024 · Paper III · Q7 (10 marks) · Dec 2025 · Paper III · Q10(a) (5 marks)	2×	65
196. Hepatic iron quantification Asked in: Jun 2025 · Paper IV · Q6(a) (5 marks)	1×	68
197. Budd–Chiari syndrome — causes, imaging, Doppler and interventional management Asked in: Jun 2020 · Paper III · Q1 (10 marks) · Dec 2022 · Paper III · Q7 (10 marks) · May 2024 · Paper II · Q6 (10 marks)	3×	70

198. Portal hypertension — interventional radiology including TIPS Asked in: Oct 2023 · Paper III · Q6 (10 marks) · Oct 2023 · Paper IV · Q2 (10 marks)	2×	75
199. Doppler in extrahepatic portal hypertension Asked in: Dec 2025 · Paper II · Q9(a) (5 marks)	1×	79
200. Preoperative imaging of donor and recipient for liver transplantation Asked in: Dec 2022 · Paper IV · Q5 (10 marks)	1×	82
201. Obstruction at the lower end of the CBD — differential diagnosis and imaging Asked in: May 2024 · Paper III · Q4 (10 marks)	1×	85
202. Portal biliopathy and primary sclerosing cholangitis Asked in: Jun 2025 · Paper III · Q10 (10 marks)	1×	91
203. Klatskin tumour (hilar cholangiocarcinoma) Asked in: Dec 2025 · Paper III · Q3(a) (5 marks)	1×	93
204. MRCP — technique, sequences and MRCP vs ERCP Asked in: Dec 2021 · Paper III · Q7(a) (5 marks) · Oct 2023 · Paper IV · Q6 (10 marks)	2×	96
205. Choledochal cyst and Caroli disease Asked in: Dec 2021 · Paper III · Q7(b) (5 marks) · Dec 2025 · Paper III · Q9(a) (5 marks)	2×	100
206. Neonatal cholestasis and biliary atresia — US, MRI and scintigraphy Asked in: Dec 2020 · Paper III · Q6 (10 marks) · Dec 2022 · Paper III · Q5 (10 marks) · Oct 2023 · Paper III · Q5 (10 marks)	3×	102
207. Acute pancreatitis — radiography, CT and MRI Asked in: Jun 2020 · Paper III · Q10(b) (5 marks) · Jun 2021 · Paper III · Q1(a) (5 marks) · Dec 2021 · Paper III · Q10(a) (5 marks)	3×	108
208. Groove pancreatitis and mass-forming pancreatitis vs pancreatic adenocarcinoma Asked in: Jun 2021 · Paper III · Q1(b) (3 marks) · Jun 2021 · Paper III · Q1(c) (2 marks) · Dec 2025 · Paper III · Q3(b) (5 marks)	3×	111
209. Complications of acute severe pancreatitis and role of interventional radiology Asked in: Dec 2022 · Paper III · Q1 (10 marks)	1×	114
210. Cystic pancreatic neoplasms — classification, imaging and side-branch IPMN Asked in: Jun 2020 · Paper III · Q5 (10 marks) · Jun 2022 · Paper III · Q10 (10 marks) · Oct 2024 · Paper III · Q1 (10 marks)	3×	121
211. Pancreatic adenocarcinoma — imaging evaluation Asked in: May 2024 · Paper III · Q5 (10 marks)	1×	125
212. Pancreatic neuroendocrine tumours — role of imaging, CT/MRI and molecular imaging Asked in: May 2024 · Paper IV · Q10(a) (5 marks) · Oct 2024 · Paper I · Q1 (10 marks)	2×	130
213. Pancreas divisum — definition, embryology and imaging Asked in: Dec 2020 · Paper III · Q9 (10 marks)	1×	137
214. Solid renal masses and renal cell carcinoma — paraneoplastic syndromes, MDCT technique and imaging Asked in: Dec 2021 · Paper III · Q1 (10 marks) · Oct 2023 · Paper III · Q3 (10 marks)	2×	140
215. Renal angiomyolipoma Asked in: Dec 2025 · Paper III · Q2(b) (5 marks)	1×	143
216. Bosniak classification of renal cysts (version 2019) — criteria, significance and drawbacks Asked in: Jun 2021 · Paper III · Q5 (10 marks) · Dec 2022 · Paper III · Q3 (10 marks) · Dec 2025 · Paper III · Q2(a) (5 marks)	3×	146
217. Renal transplant — donor work-up, graft dysfunction and complications on US, Doppler and scintigraphy Asked in: Jun 2020 · Paper III · Q2 (10 marks) · Jun 2022 · Paper III · Q1 (10 marks) · Oct 2023 · Paper III · Q9 (10 marks)	3×	150
218. Genitourinary tuberculosis — pathophysiology and imaging Asked in: Jun 2022 · Paper III · Q7 (10 marks) · Jun 2025 · Paper III · Q8 (10 marks)	2×	155
219. Nephrocalcinosis — causes and imaging Asked in: Jun 2022 · Paper III · Q5 (10 marks)	1×	161
220. Haematuria in a 40-year-old woman — role of imaging Asked in: Apr 2023 · Paper III · Q10 (10 marks)	1×	164

221. MR urography — technique, sequences, applications, advantages and disadvantages Asked in: Dec 2020 · Paper IV · Q2 (10 marks) · Jun 2022 · Paper IV · Q5 (10 marks)	2×	169
222. Vesicoureteric reflux — evaluation Asked in: Dec 2025 · Paper III · Q5(b) (5 marks)	1×	173
223. Carcinoma bladder — TNM/T staging with diagram, multiparametric MRI and VI-RADS Asked in: Jun 2020 · Paper III · Q6 (10 marks) · Dec 2021 · Paper III · Q2(a) (5 marks) · Dec 2025 · Paper III · Q4 (10 marks)	3×	175
224. Bladder outlet obstruction and difficulty in micturition in an older man — imaging approach Asked in: Jun 2022 · Paper III · Q2 (10 marks) · May 2024 · Paper III · Q6 (10 marks)	2×	179
225. Prostate — zonal anatomy, role of MRI and PI-RADS Asked in: Apr 2023 · Paper III · Q8 (10 marks)	1×	184
226. Male urethra — radiological anatomy and evaluation of abnormalities Asked in: Jun 2025 · Paper III · Q9 (10 marks)	1×	189
227. Male infertility — causes and role of imaging Asked in: Dec 2020 · Paper III · Q2(a) (6 marks) · Dec 2022 · Paper III · Q4 (10 marks)	2×	196
228. Erectile dysfunction — penile Doppler technique, findings and limitations Asked in: Dec 2020 · Paper III · Q2(b) (4 marks) · Jun 2022 · Paper II · Q10 (10 marks) · Oct 2023 · Paper III · Q10 (10 marks)	3×	202
229. Acute scrotum — differential diagnosis and colour Doppler in torsion Asked in: Apr 2023 · Paper II · Q3(b) (5 marks) · Dec 2025 · Paper II · Q6 (10 marks)	2×	207
230. Cushing syndrome — causes and imaging work-up Asked in: Dec 2020 · Paper I · Q1(a) (5 marks) · Dec 2022 · Paper I · Q10 (10 marks)	2×	212
231. Adrenal lesions — CT protocol and adenoma vs metastasis Asked in: Dec 2020 · Paper I · Q1(b) (5 marks) · Apr 2023 · Paper III · Q6 (10 marks)	2×	217
232. Phaeochromocytoma Asked in: Dec 2025 · Paper III · Q9(b) (5 marks)	1×	223
233. Ectopic pregnancy and first-trimester bleeding — ultrasound, algorithm and mimics Asked in: Jun 2020 · Paper III · Q4 (10 marks) · Dec 2021 · Paper III · Q6(a) (5 marks) · Jun 2022 · Paper III · Q4 (10 marks) · Dec 2025 · Paper III · Q8(a) (5 marks)	4×	225
234. First-trimester ultrasound — indications and anomaly assessment Asked in: Apr 2023 · Paper III · Q3 (10 marks)	1×	230
235. Gestational trophoblastic disease and hydatidiform mole Asked in: Jun 2021 · Paper III · Q8 (10 marks) · Dec 2025 · Paper III · Q8(b) (5 marks)	2×	234
236. Incompetent cervical os — sonographic evaluation Asked in: Jun 2025 · Paper III · Q7(b) (5 marks)	1×	237
237. Fetal growth restriction — ultrasound and Doppler (uterine artery, umbilical artery, MCA, ductus venosus) Asked in: Apr 2023 · Paper II · Q5(a) (5 marks) · Apr 2023 · Paper III · Q7 (10 marks) · Jun 2025 · Paper III · Q4 (10 marks) · Dec 2025 · Paper II · Q9(b) (5 marks)	4×	240
238. Oligohydramnios — ultrasound findings Asked in: Dec 2021 · Paper III · Q6(b) (5 marks)	1×	246
239. Polyhydramnios at 28 weeks — causes and imaging evaluation Asked in: Oct 2024 · Paper III · Q10 (10 marks)	1×	248
240. Twin pregnancy in the third trimester — ultrasound and Doppler Asked in: May 2024 · Paper III · Q7 (10 marks)	1×	254
241. Placenta accreta spectrum and placental variants — US and MRI Asked in: Dec 2021 · Paper III · Q5 (10 marks) · Oct 2023 · Paper III · Q2 (10 marks) · May 2024 · Paper III · Q9 (10 marks)	3×	261
242. Postpartum haemorrhage — causes, imaging and interventional radiology Asked in: Dec 2025 · Paper III · Q6 (10 marks)	1×	266
243. Fetal MRI — indications, safety, protocol, advantages and disadvantages Asked in: Jun 2020 · Paper III · Q7 (10 marks) · Dec 2021 · Paper III · Q9(b) (5 marks)	2×	271
244. Fetal MRI in posterior fossa anomalies Asked in: May 2024 · Paper III · Q10 (10 marks)	1×	276

245. Fetal MRI technique and indications, and its role in fetal renal anomalies Asked in: Oct 2024 · Paper III · Q4 (10 marks)	1×	281
246. Acute pelvic pain in a young woman and ovarian torsion — causes and imaging Asked in: Dec 2020 · Paper III · Q1 (10 marks) · Jun 2022 · Paper II · Q9 (10 marks) · Oct 2024 · Paper II · Q2 (10 marks)	3×	285
247. Ovarian mass — MRI algorithm, cystic masses and benign vs malignant features Asked in: Jun 2021 · Paper III · Q6 (10 marks) · Dec 2025 · Paper III · Q1 (10 marks)	2×	291
248. O-RADS — lexicon and risk stratification Asked in: May 2024 · Paper III · Q8 (10 marks)	1×	297
249. Postmenopausal bleeding and endometrial carcinoma — imaging, differential diagnosis and staging Asked in: Dec 2020 · Paper III · Q3 (10 marks) · Dec 2021 · Paper III · Q4 (10 marks) · Apr 2023 · Paper III · Q4 (10 marks)	3×	301
250. Carcinoma cervix — role of imaging and MRI in diagnosis and staging Asked in: Dec 2021 · Paper III · Q9(a) (5 marks) · Jun 2025 · Paper III · Q6 (10 marks)	2×	307
251. Female infertility — TVS, HSG and MRI, and MRI of adenomyosis Asked in: Jun 2021 · Paper III · Q9 (10 marks) · Oct 2023 · Paper III · Q7 (10 marks)	2×	313
252. Hysterosalpingography — technique, indications, contraindications and complications Asked in: Jun 2021 · Paper IV · Q10 (10 marks)	1×	319
253. Follicular monitoring by ultrasound — technique, indications and findings Asked in: Oct 2024 · Paper III · Q8 (10 marks)	1×	322
254. Sonohysterosalpingography Asked in: Jun 2025 · Paper III · Q7(a) (5 marks)	1×	326
255. Müllerian duct anomalies — classification and imaging Asked in: Dec 2022 · Paper III · Q10 (10 marks)	1×	328
256. Primary amenorrhoea — investigations and imaging in one condition Asked in: Oct 2023 · Paper III · Q8 (10 marks)	1×	334
257. Endometriosis — TVS and MRI Asked in: Oct 2024 · Paper III · Q5 (10 marks)	1×	338
258. Uterine fibroids — MRI mapping and interventional radiology Asked in: Jun 2025 · Paper IV · Q1 (10 marks)	1×	344

C · High-yield list — whole book (asked 3× or more)

145. Ischaemic heart disease — cardiac MRI, viability, nuclear imaging and MDCT	5×	Vol II, p. 193
152. Plain radiograph in rheumatic and mitral valve disease and left atrial enlargement	5×	Vol II, p. 223
1. X-ray tube — construction, X-ray production and tube failure	4×	Vol I, p. 10
13. Dual-energy CT — principle, acquisition methods and applications including pulmonary	4×	Vol I, p. 45
44. Iodinated contrast media — classification, adverse reactions and management including emergency drugs and anaphylaxis	4×	Vol I, p. 149
74. Breast MRI — indications, technique, advantages, limitations, non-mass enhancement and benign vs malignant	4×	Vol I, p. 240
94. Embolic agents — classification, advantages, disadvantages and clinical applications	4×	Vol I, p. 315
126. Mediastinal compartments (ITMIG), anterior mediastinal masses and thymoma	4×	Vol II, p. 115
158. Acute mesenteric ischaemia — causes, imaging and endovascular management	4×	Vol II, p. 246
233. Ectopic pregnancy and first-trimester bleeding — ultrasound, algorithm and mimics	4×	225
237. Fetal growth restriction — ultrasound and Doppler (uterine artery, umbilical artery, MCA, ductus venosus)	4×	240
259. Acute ischaemic stroke — CT and MRI features, imaging algorithm and interventional radiology	4×	Vol IV, p. 9
8. Computed radiography and digital radiography — principles, advantages and disadvantages	3×	Vol I, p. 30
14. CT dose — CTDIvol, DLP and dose reduction in CT and radiography	3×	Vol I, p. 50

22. Colour Doppler — principle, Nyquist limit and artefacts and their prevention	3×	Vol I, p. 76
23. Ultrasound elastography — principles, techniques and applications including diffuse liver disease	3×	Vol I, p. 81
31. MRI artefacts, including motion artefacts and their reduction	3×	Vol I, p. 106
34. MRI safety — hazards, zoning of the MRI facility and safety considerations	3×	Vol I, p. 115
38. MR angiography — time-of-flight and phase-contrast principles, applications and pitfalls	3×	Vol I, p. 131
49. Ultrasound contrast agents — composition, generations, mechanism, applications, advantages and limitations	3×	Vol I, p. 169
51. Radiation protection — cardinal principles and protection of staff, patients and public	3×	Vol I, p. 176
56. Thermoluminescent dosimeter (TLD) badge — principles and uses	3×	Vol I, p. 188
70. Artificial intelligence in radiology	3×	Vol I, p. 226
82. Acute aortic syndrome and aortic dissection — classification, CT angiography and management	3×	Vol I, p. 266
86. Peripheral arterial disease — imaging modalities, CTA and MRA technique, and Doppler findings	3×	Vol I, p. 286
88. Renal artery stenosis — US, Doppler, MR angiography and intervention	3×	Vol I, p. 295
90. Varicose veins and venous incompetence — Doppler and interventional treatment	3×	Vol I, p. 301
92. Peripheral vascular malformations — diagnostic approach, Doppler and MRI, and interventional management	3×	Vol I, p. 308
95. Radiofrequency ablation — principle, indications, contraindications, complications and applications	3×	Vol I, p. 319
108. Acute pulmonary thromboembolism — pathophysiology, CT pulmonary angiography and imaging findings	3×	Vol II, p. 36
114. Haemoptysis — causes, imaging and interventional radiology	3×	Vol II, p. 59
117. Secondary pulmonary lobule, HRCT patterns of interstitial lung disease and usual interstitial pneumonia	3×	Vol II, p. 73
125. Cystic and cavitating lung lesions on CT — differential diagnosis	3×	Vol II, p. 111
137. Diaphragm — anatomy and traumatic injury on radiograph, US, CT and MRI; hernia vs eventration	3×	Vol II, p. 159
149. Congenital heart disease on the plain chest radiograph	3×	Vol II, p. 212
190. Segmental anatomy of the liver, triple-phase CT and imaging of hepatocellular carcinoma	3×	42
191. LI-RADS — categories, major and ancillary features, settings of use and role in management	3×	46
197. Budd–Chiari syndrome — causes, imaging, Doppler and interventional management	3×	70
206. Neonatal cholestasis and biliary atresia — US, MRI and scintigraphy	3×	102
207. Acute pancreatitis — radiography, CT and MRI	3×	108
208. Groove pancreatitis and mass-forming pancreatitis vs pancreatic adenocarcinoma	3×	111
210. Cystic pancreatic neoplasms — classification, imaging and side-branch IPMN	3×	121
216. Bosniak classification of renal cysts (version 2019) — criteria, significance and drawbacks	3×	146
217. Renal transplant — donor work-up, graft dysfunction and complications on US, Doppler and scintigraphy	3×	150
223. Carcinoma bladder — TNM/T staging with diagram, multiparametric MRI and VI-RADS	3×	175
228. Erectile dysfunction — penile Doppler technique, findings and limitations	3×	202
241. Placenta accreta spectrum and placental variants — US and MRI	3×	261
246. Acute pelvic pain in a young woman and ovarian torsion — causes and imaging	3×	285

249. Postmenopausal bleeding and endometrial carcinoma — imaging, differential diagnosis and staging	3×	301
260. Subarachnoid haemorrhage — causes, subarachnoid spaces, imaging evaluation and endovascular treatment of aneurysm	3×	Vol IV, p. 14
277. Epilepsy imaging — protocol, mesial temporal sclerosis, advanced MR and nuclear techniques	3×	Vol IV, p. 83
300. Sensorineural hearing loss in a child — inner ear anatomy and imaging work-up	3×	Vol IV, p. 177
314. Thyroid nodule — ultrasound evaluation and TI-RADS	3×	Vol IV, p. 229
325. Hyperparathyroidism — types, skeletal radiography, renal osteodystrophy and primary vs secondary	3×	Vol IV, p. 279
327. Rickets and osteomalacia — radiographic features	3×	Vol IV, p. 290
342. Cartilage imaging techniques and osteochondral lesions	3×	Vol IV, p. 342

PART 15

Body trauma

182. Abdominal trauma — imaging approach and FAST, including extended FAST in chest trauma

ASKED 2× · 10-mark answer

Asked in: Jun 2021 · Paper II · Q4(a) (5 marks) · Dec 2022 · Paper II · Q1 (10 marks)

Q: What is the imaging approach to a patient with abdominal trauma? [5]

Q: Discuss the technique and limitations of Focussed Assessment with Sonography in Trauma (FAST). Discuss the extended use of FAST in chest in a case of blunt trauma. [4+(2+4)]

SOURCE

GA V1 — Ch 10 Thoracic Trauma and Related Topics — §Introduction — p. 231
GA V2 — Ch 71 Paediatric Abdominal Imaging — §Spleen, Trauma — p. 1843
AMP V2 — Ch 116 Imaging in Abdominal Trauma — §Ultrasonography — e.4558–e.4559
[W1] ACS Committee on Trauma — Advanced Trauma Life Support (ATLS), 11th edition — 2025 — https://www.facs.org/quality-programs/trauma/education/advanced-trauma-life-support/about/
[W2] ACEP — Ultrasound guidelines: emergency, point-of-care, and clinical ultrasound guidelines in medicine — Ann Emerg Med 2023;82:e115–e155 — https://www.acep.org/by-medical-focus/ultrasound/
[W3] RSNA RadioGraphics — Grading Abdominal Trauma: Changes in and Implications of the Revised 2018 AAST-OIS for the Spleen, Liver, and Kidney — RadioGraphics 2023;43(9):e230040 — https://pubs.rsna.org/doi/10.1148/rg.230040
[W4] WSES — Follow-up strategies for patients with splenic trauma managed non-operatively: the 2022 WSES consensus document — 2022 — https://link.springer.com/article/10.1186/s13017-022-00457-5

Imaging approach to abdominal trauma

- **Primary survey first.** Major trauma is managed by the ATLS protocol. The 11th edition was released in 2025.
- **Initial radiographs.** The primary radiological assessment is an AP chest and AP pelvis radiograph.
  - If a major injury is suggested and the patient is relatively stable, many centres omit these and go straight to "trauma series" MDCT.
  - The chest radiograph can also show pneumoperitoneum. As little as 1 cc of free air can be seen on an upright film. A supine film is insensitive.
  - The pelvic radiograph looks for pelvic fractures.
- **FAST** is the bedside screen for free fluid. It can be done in transit by a competent operator.
- **Fast helical MDCT** is the most useful investigation in the acute setting. It is rapid, available and familiar to the radiologist.
  - Anaesthetic and monitoring equipment is available in most emergency CT units, so even relatively unstable patients can be scanned.
  - Protocols vary. All include unenhanced CT head and contrast-enhanced thorax and abdomen, with full spine and pelvis.
  - Some centres use a two-phase single acquisition from skull base to mid-femur. A dilute agent gives the portovenous phase and a concentrated agent injected slightly later gives an arterial phase. This also gives neck and intracranial angiographic images.
- **Stable versus unstable.**
  - A haemodynamically stable patient with positive FAST should have injuries staged with CT, which allows non-operative management where possible.
  - A positive FAST does not necessarily mandate laparotomy.
  - Contrast-enhanced US (CEUS) detects hepatic, splenic and renal injuries, including vascular injuries. It cannot assess bowel, mesentery or retroperitoneum.
- **Reporting.** A quick provisional proforma is given to the emergency physician within 15 minutes. It has a "tick-box" entry for each injury-free body part and a brief description of any injury.
- **Children.** Reduce radiation dose.
  - Volume and rate of contrast are tailored to body weight.
  - Without CXR signs of severe trauma, CT can sometimes be avoided.

- Imaging is otherwise similar to adults. FAST has a low (50%) negative predictive value for abdominal injury in stable children compared with CT.

Table 1: Modality comparison in abdominal trauma

Modality	Findings	Strength	Limit
Radiograph	Pneumoperitoneum, pelvic fracture	Fast, first line	Supine film insensitive for free air
FAST	Free fluid, pericardial fluid	Minutes, bedside	Not for organ lesions or retroperitoneum
CEUS	Solid organ and vascular injury	Alternative to CECT	Bowel, mesentery, retroperitoneum not assessable
MDCT	All organ injury, vascular injury, active bleeding	Most useful acutely	Many images, delayed report

Flowchart 1: Imaging pathway in abdominal trauma

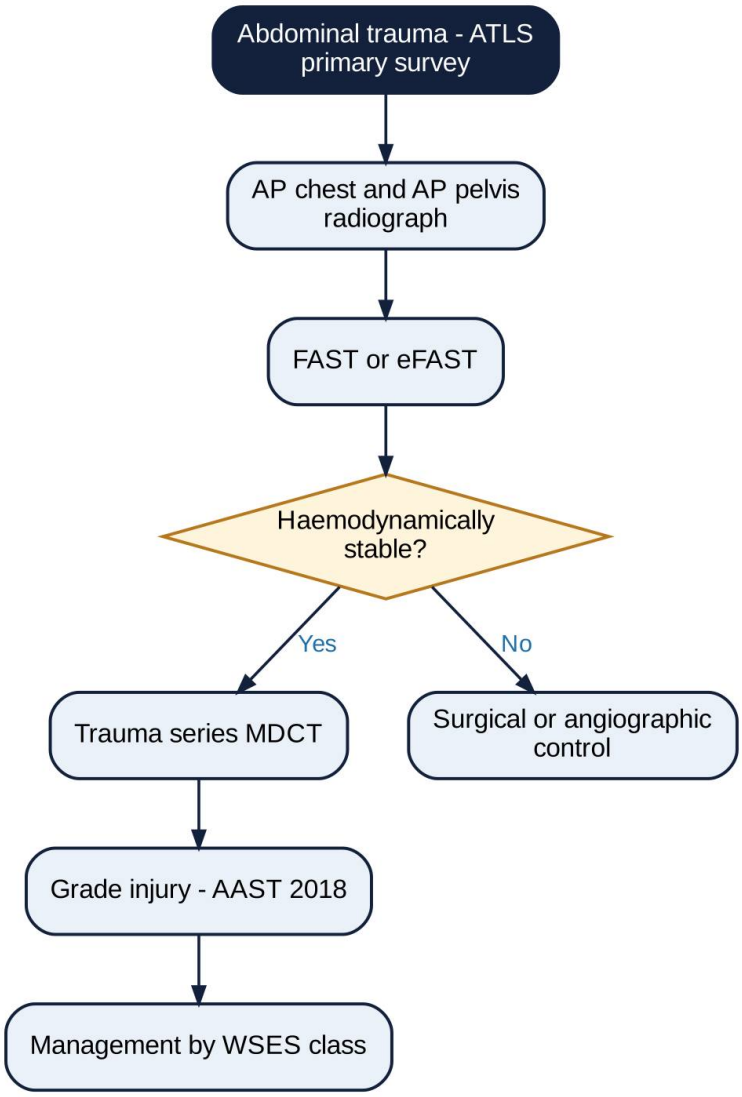

Grading on CT

- The 2018 AAST OIS grades solid organ injury on imaging, operative and pathology criteria. The final grade is the highest of the three.
- Multiple grade I or II injuries in one organ advance the grade to III.
- The main change is the addition of MDCT vascular injury, meaning pseudoaneurysm and arteriovenous fistula.

Table 2: AAST OIS 2018, higher grades

Grade	Liver	Spleen	Kidney
III	Laceration >3 cm depth, or contained vascular injury	Laceration >3 cm, or haematoma ≥5 cm	Laceration >1 cm, no collecting system rupture
IV	25–75% lobe disruption, or bleeding into peritoneum	Vascular injury, or >25% devascularisation	Collecting system laceration with extravasation, segmental vessel injury
V	>75% lobe disruption, or juxtahepatic venous injury	Shattered, or vascular injury with bleeding into peritoneum	Shattered, devascularised, or hilar avulsion

- Use the AAST 2018 grade for imaging and the WSES class for management.
- In stable patients with arterial blush on CT, splenic artery embolisation is first-line irrespective of grade.

FAST – technique and limitations

Technique

- FAST is a fast overview of the abdomen to detect free fluid, which indicates haemoperitoneum and visceral injury. It should be completed within a few minutes.
- Search for organ injury must not delay the examination when haemorrhage is suspected.
- Four regions are examined in order: pericardium, right upper quadrant, left upper quadrant, pelvis.
- Standard views:
  - **Epigastric transverse:** pericardial fluid and the left lobe of liver.
  - **Right upper quadrant longitudinal:** right liver lobe, right kidney, **Morison's pouch** and perihepatic fluid.
  - **Left upper quadrant longitudinal:** spleen, left kidney, perisplenic fluid.
  - **Flank longitudinal:** paracolic gutters.
  - **Suprapubic transverse and longitudinal:** bladder, pelvic fluid, pouch of Douglas.
- Appearance of hemoperitoneum is lenticular in the subphrenic space, triangular in Morison's pouch and ovoid in the pelvis.

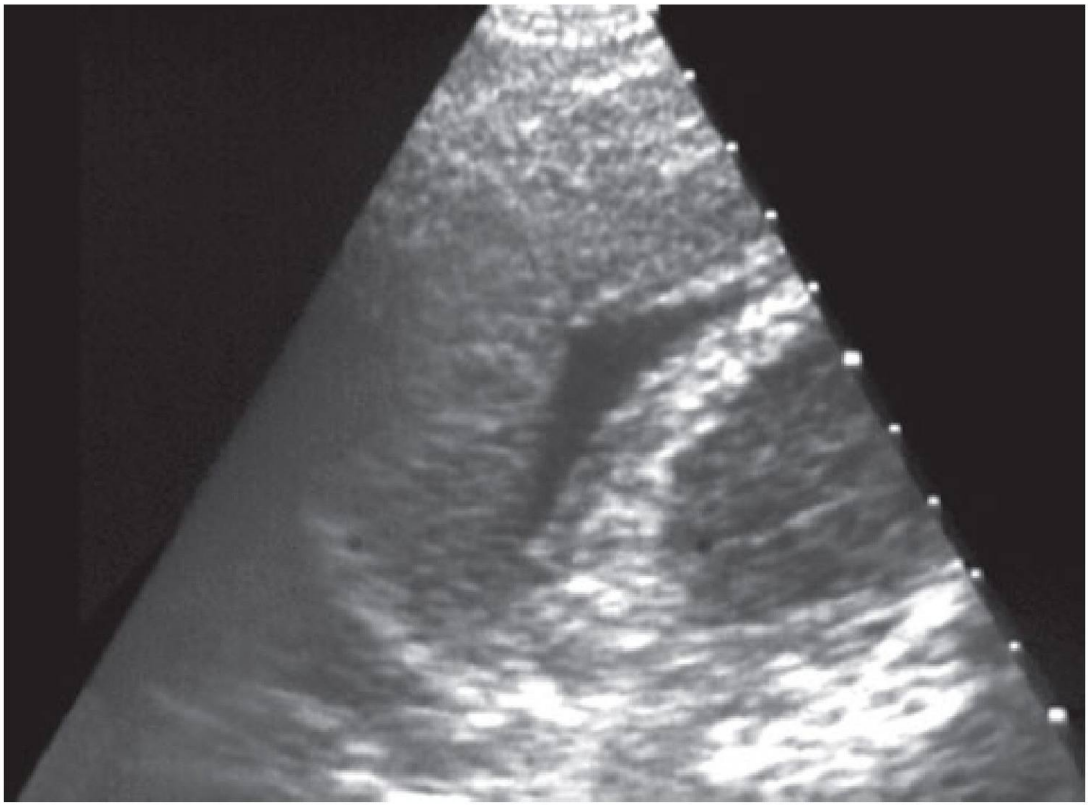

FIG. 1 — AMP V2, e-book p. 4559. Axial ultrasound image shows free fluid in hepatorenal pouch.

Limitations

- FAST gives a yes/no answer on bleeding. It is not meant to quantify bleeding or assess organ lesions.

- FAST detects haemopericardium and haemoperitoneum with sensitivity of 85%–96% and specificity >98%.
- A negative FAST means no haemoperitoneum, not no intra-abdominal injury. Its sensitivity for free fluid is less than CT.
  - The average false-negative rate for free fluid is about 15%.
  - A negative FAST is viewed with suspicion if it does not fit the clinical picture.
- It is unreliable for the retroperitoneum.
- Sensitivity for organ injury is poor.
  - Liver: it misses an average of 15% of injuries.
  - Spleen: sensitivity is 37–85%, with a false-negative rate over 50%.
  - Kidney and pancreas: lower than liver and spleen.
  - Bowel and mesentery: lower still.
- Hence US is not recommended as a modality for detecting abdominal injuries.
- In stable children, the negative predictive value for abdominal injury is only 50%.

Extended use of FAST (eFAST) in chest in blunt trauma

- **eFAST** adds the pleural spaces as a fifth region to the four FAST regions.
- Bilateral longitudinal thoracic views are used to look for **pleural effusion**, which in blunt trauma means haemothorax.
- The **pericardial** window is part of FAST itself. Sensitivity for pericardial effusion is high (97–100%).
- In transit, competent operators can detect pleural and pericardial fluid before arrival in the emergency department.
- This allows early decisions on chest drainage or pericardial intervention.
- Limits:
  - eFAST detects only fluid. A chest radiograph is still needed for chest injuries.
  - CT remains the definitive study. Fast helical MDCT is the most useful acute imaging investigation.

PEARLS

- FAST is a four-window (pericardium, RUQ, LUQ, pelvis) screen for free fluid. eFAST adds the pleural spaces as the fifth.
- The first fluid-collecting site is **Morison's pouch**.
- Negative FAST means no haemoperitoneum, not no injury. It misses retroperitoneal, bowel and many splenic injuries.
- Stable patient with positive FAST: stage with MDCT and consider non-operative management.
- Trauma CT: unenhanced head plus contrast thorax and abdomen with spine and pelvis. A two-phase protocol adds an arterial phase.
- Grade with AAST 2018 (vascular injury now included) and manage by WSES class.
- Exam trap: FAST in stable children has only 50% NPV against CT.

183. Splenic trauma — imaging findings and AAST grading

ASKED 2× · 10-mark answer

Asked in: Jun 2021 · Paper II · Q4(b) (5 marks) · Jun 2025 · Paper II · Q10 (10 marks)

Q: Describe the imaging findings in splenic trauma. [5]

Q: Describe the imaging findings as seen in splenic trauma with the AAST classification of splenic injuries. [10]

SOURCE

GA V1 — Ch 23 The Liver and Spleen — §Complications and Safety; §Spleen — Anatomy and Acquired Diseases — pp. 645–648
AMP V2 — Ch 116 Imaging in Abdominal Trauma — §Spleen — e.4573
AMP V2 — Ch 118 Imaging of Spleen — §Splenic Rupture — e.4699
CORE — Ch 2 Gastrointestinal Imaging — §Splenic trauma — pr.170
[W1] RSNA RadioGraphics — Grading Abdominal Trauma: Changes in and Implications of the Revised 2018 AAST-OIS for the Spleen, Liver, and Kidney — 2023 — https://pubs.rsna.org/doi/10.1148/rg.230040
[W2] ACEP — Ultrasound guidelines: emergency, point-of-care, and clinical ultrasound guidelines in medicine — 2023 — https://www.acep.org/by-medical-focus/ultrasound/

Imaging findings in splenic trauma

Role and technique

- The spleen is frequently injured in abdominal trauma, and both acute and delayed rupture can cause life-threatening haemorrhage.
- **Multiphase contrast-enhanced CT** is the established technique for diagnosis and grading, with sensitivity and specificity above 95%.
- The normal spleen shows a **striped (zebra) enhancement** pattern in the early parenchymal phase. It becomes homogeneous in the venous and later phases.
- Judge injury on the portal venous phase, because arterial-phase heterogeneity can mask or mimic injury.
- Prominent lateral and inferior **clefts** may simulate lacerations.
- The spleen is the most commonly injured organ in blunt abdominal trauma. Most patients also have other intra-abdominal injuries.

CT findings

- **Laceration**: a linear low-attenuation parenchymal defect, almost always associated with haemoperitoneum.
  - On CT it appears as a linear or branching area of decreased attenuation.
  - A laceration crossing two capsular surfaces is termed a **fracture**.
- **Parenchymal haematoma**: on unenhanced CT it may be hyperdense or isodense to parenchyma, but it does not enhance after contrast.
- **Subcapsular or perisplenic haematoma**: a crescentic, well-defined collection along the splenic margin. It indicates significant injury even without a parenchymal defect.
- **Active bleeding**: a focal area of enhancement within a haematoma.
  - It is initially iso-enhancing to the arterial blood pool and increases in size or attenuation on delayed scans as blood pools.
- **Contained vascular injury** (pseudoaneurysm or AV fistula): a focal hyperattenuating area that does not enlarge on delayed scanning.
  - CT cannot separate pseudoaneurysm from AV fistula. Angiography is needed.
- **Shattered spleen**: multiple fragments with a surrounding hyperdense perisplenic haematoma.
  - Coronal reformats can show focal extravasation, for example at the inferior pole.

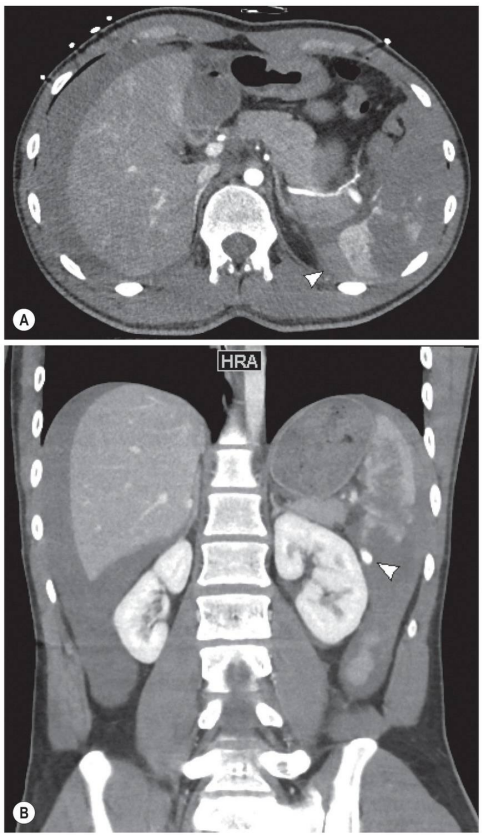

Fig. 23.76 — GA V1, p. 648. Splenic Trauma. Axial contrast-enhanced CT (A) demonstrates shattered spleen with perisplenic hyperdense haematoma (arrowhead) after a high-speed motor vehicle accident. Coronal reformation (B) demonstrates focal extravasation at the inferior pole of the spleen as the source of haemorrhage. Splenectomy was necessary to control bleeding.

Ultrasound findings

- Organised haematoma appears as a well-defined hypoechoic area.
- US is not sensitive enough to reliably exclude significant splenic injury after trauma.
- It is useful for following haematoma resolution.
- FAST examines the pericardium, right upper quadrant, left upper quadrant and pelvis. It gives a yes/no answer on free blood and is not meant to assess organ lesions.
- On US, perisplenic fluid with internal echoes, subcapsular haematoma and a hypoechoic laceration may be seen.

MRI findings

- MRI is rarely used in acute trauma.
- It demonstrates haematomas, with signal depending on the phase of blood-product degradation.

AAST classification of splenic injuries (2018 OIS)

- The 2018 OIS grades injury on imaging, operative and pathology criteria, and the final grade is the highest of the three.
- Multiple grade I or II injuries in one spleen advance the grade to III.
- The main change from the older scale is the addition of **MDCT vascular injury** (pseudoaneurysm, AV fistula).

Table 1: AAST organ injury scale for the spleen, 2018 revision (imaging criteria)

Grade	Criteria
I	Subcapsular haematoma <10%; laceration <1 cm depth or capsular tear
II	Subcapsular haematoma 10–50%; intraparenchymal haematoma <5 cm; laceration 1–3 cm
III	Subcapsular haematoma >50%; ruptured subcapsular or intraparenchymal haematoma ≥5 cm; laceration >3 cm depth
IV	Any splenic vascular injury (pseudoaneurysm or AV fistula) or active bleeding confined within the splenic capsule; laceration involving segmental or hilar vessels with >25% devascularisation
V	Shattered spleen; or any splenic vascular injury with active bleeding extending beyond the spleen into the peritoneum

Table 2: Older book scale versus current scale

Book (AMP, 3rd ed.)	Current (AAST, 2018)
The AAST scale is based on appearance of the spleen at surgery and ignores CT vascular injury.	CT vascular injury is graded. Pseudoaneurysm, AV fistula or contained bleeding is grade IV. Bleeding into the peritoneum is grade V.
Marmery's modified grading: active intraparenchymal or subcapsular bleeding, vascular injury and shattered spleen are IVa. Active intraperitoneal bleeding is IVb. There is no grade V.	The 2018 scale keeps grade V.

How to apply it

- Active haemorrhage and vascular injury predict the need for splenic artery embolisation or surgery.
- Splenic preservation is now favoured because post-splenectomy pneumococcal infection is more severe.
- Report the following in every case:
  - grade
  - haematoma size and extent
  - vascular injury or active bleeding, and whether it is contained
  - haemoperitoneum

PEARLS

- CT is the investigation of choice: multiphase contrast CT, with the portal venous phase for injury assessment.
- Classic signs: a linear low-attenuation **laceration**, a crescentic **subcapsular haematoma**, and a focal blush of **active extravasation** that grows on delay.
- Pseudoaneurysm and AV fistula stay the same size on delayed scans, unlike active extravasation.
- Exam trap: clefts and early striped enhancement mimic laceration.
- Exam trap: US and FAST cannot exclude significant splenic injury.
- AAST 2018: any vascular injury makes the injury at least grade IV, and a shattered spleen is grade V.

184. Liver injury — AAST scale and delayed complications

ASKED 1× · 10-mark answer

Asked in: Oct 2023 · Paper II · Q10 (10 marks)

Q: Describe the latest AAST liver injury scale. What are the delayed complications of injury to the liver? [4+6]

SOURCE

GA V1 — Ch 23 The Liver and Spleen — §Hepatic Trauma, §Living Donor Assessment — pp. 641–642
AMP V2 — Ch 116 Imaging in Abdominal Trauma — §Liver and Biliary Tract, §CT Signs for Operative/Angiographic Intervention — e.4572, e.4575, e.4579
[W1] RSNA RadioGraphics — Grading Abdominal Trauma: Changes in and Implications of the Revised 2018 AAST-OIS for the Spleen, Liver, and Kidney — 2023 (RadioGraphics 43(9):e230040) — https://pubs.rsna.org/doi/10.1148/rg.230040

Latest AAST liver injury scale

- The latest version is the **AAST Organ Injury Scale, 2018 update** (liver, spleen and kidney).
- The 2018 scale is graded on imaging, operative and pathology criteria, and the final grade is the highest of the three.
- Multiple grade I or II injuries in one liver advance the grade to III.
- The main change from the older scale is that MDCT vascular injury (pseudoaneurysm, arteriovenous fistula) is now graded.
- Prompt multiphase CT is the technique of choice. Arterial and portal phases are mandatory to detect arterial injury, subtle lacerations and hilar involvement.

Table 1: AAST liver injury scale (2018 update), imaging criteria

Grade	Criteria
I	Subcapsular haematoma <10% of surface area, or laceration <1 cm
II	Subcapsular haematoma 10–50%, intraparenchymal haematoma <10 cm, or laceration 1–3 cm
III	Subcapsular haematoma >50% or ruptured subcapsular/parenchymal haematoma; intraparenchymal haematoma >10 cm; laceration >3 cm deep; any liver vascular injury or active bleeding contained within the parenchyma
IV	Parenchymal disruption of 25–75% of a hepatic lobe, or active bleeding extending beyond the parenchyma into the peritoneum
V	Parenchymal disruption >75% of a lobe, or juxtahepatic venous injury (retrohepatic IVC, central major hepatic veins)
VI	Hepatic avulsion

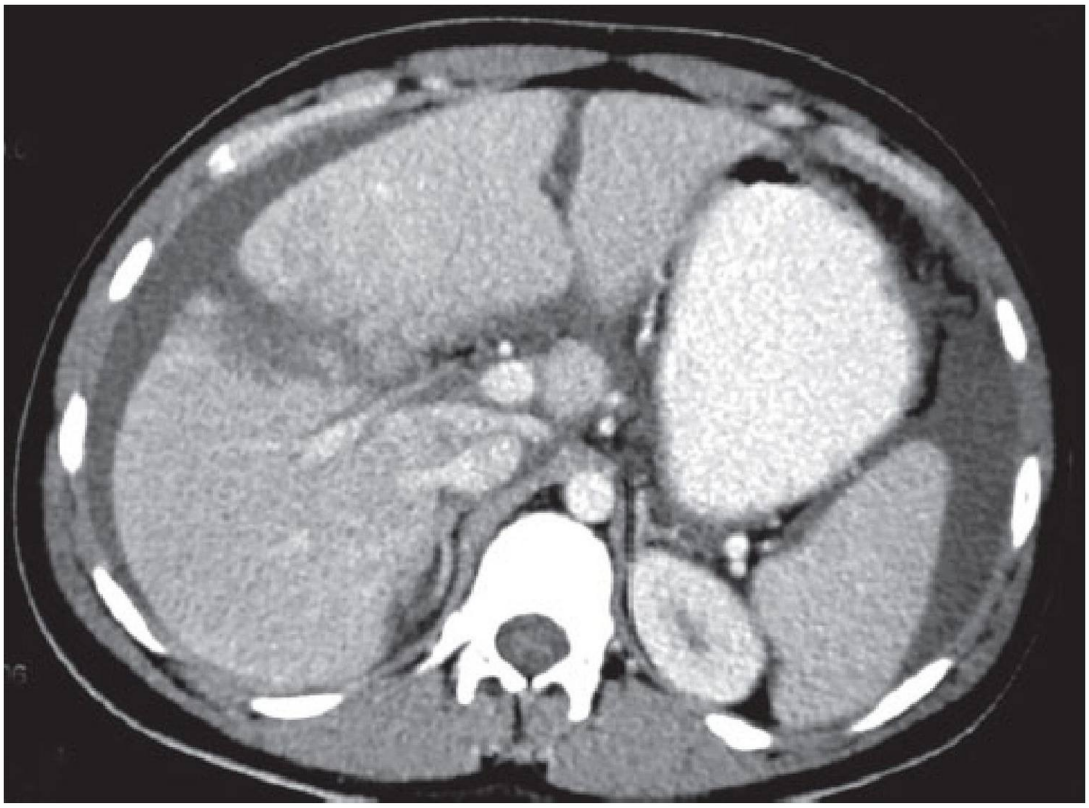

FIG. 9 — AMP V2, e-book p. 4572. Axial CECT scan shows a linear liver laceration

Imaging points for applying the scale

- **Laceration** is the commonest liver injury. It runs along the portal and hepatic vein planes and fissures, which are anatomical weak zones.
- Lacerations are classed as superficial (≤3 cm) or deep (>3 cm).
- Intraparenchymal lacerations and haematomas are usually elliptical or linear. Lacerations involving major vessels are rare but can cause life-threatening haemorrhage.
- Fresh thrombus (the "sentinel clot") is higher in attenuation than normal blood and points to the nearby bleeding source.
- **Periportal tracking** is low density along the portal branches. With an adjacent laceration it indicates blood tracking along the periportal tissue.
- Grade 4/5 liver injuries are relative indications for surgical or angiographic intervention.
- The scale does not assess biliary injury. Hepatic scintigraphy and MRCP help to detect bile leaks.

Delayed complications of liver injury

- Conservative management is now used in most liver injuries, including severe grades. Delayed complications are therefore seen more often on follow-up CT.
- Secondary problems listed by Grainger & Allison are ischaemia, necrosis of part of the liver, abscess, haemobilia, focal fibrosis, calcification and lobar or segmental atrophy.

Table 2: Delayed complications and their imaging

Complication	Mechanism	Imaging
Delayed haemorrhage	Rupture of a pseudoaneurysm, or an initially minimal injury that expands	Expanding haematoma, new haemoperitoneum
Hepatic artery pseudoaneurysm	Arterial continuity is disrupted and blood extravasates into a parenchymal haematoma, which forms a fibrous capsule	Focal rounded enhancing lesion that follows arterial blood attenuation in all phases
Haemobilia	Pseudoaneurysm ruptures into the biliary system	Hyperdense blood in intrahepatic ducts and CBD. It may present as haematemesis or melaena after drainage into the duodenum
Abscess	Seen in follow-up of high-grade injuries	Fluid-containing focal lesion with air bubbles or air-fluid levels
Biloma	Bile leaks into a haematoma and necroses the surrounding liver	Low-attenuation, well-circumscribed collection. HIDA scintigraphy confirms the leak;
Biliary peritonitis	Bile leaks into the peritoneal cavity	Peritoneal thickening and enhancement with increasing low-attenuation fluid
Ischaemia, necrosis, fibrosis, calcification, atrophy	Late parenchymal sequelae	Non-enhancing or shrunken segment or lobe, focal scar, calcification
Arteriovenous shunt	Arteriovenous shunts may follow trauma	Early hepatic vein enhancement on the arterial phase; Doppler US and arterial-phase CT or MRI show the shunt

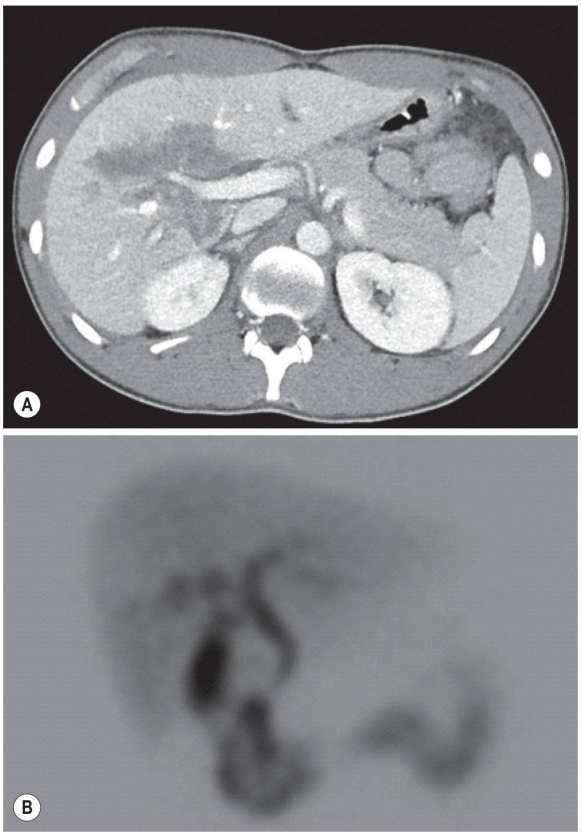

Fig. 23.69 *— GA V1, p. 642. Liver Laceration. Large central laceration on CT (A) after motor vehicle accident showing hypodense disruption of central right hepatic lobe, resulting in a large biloma days later, proven by biliary leakage on HIDA scintigram (B).*

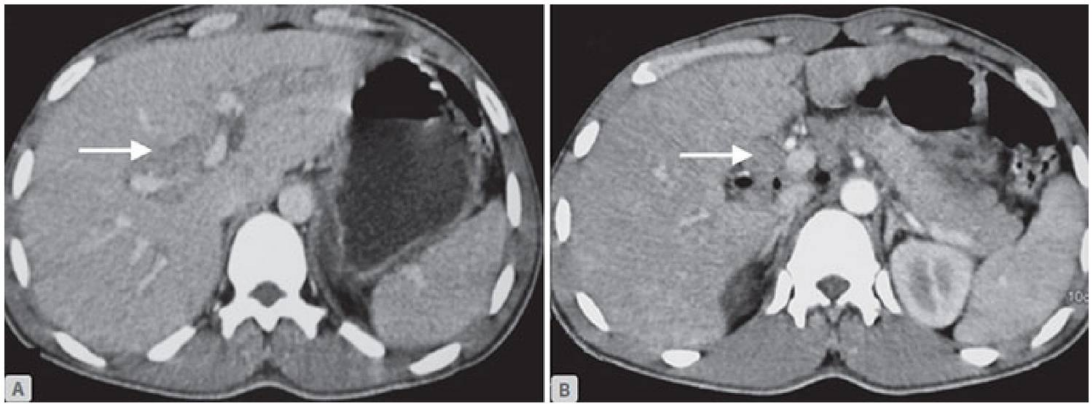

***FIGS. 15A AND B** — AMP V2, e-book p. 4579. FIGS. 15A AND B: Axial CECT scans through upper abdomen show hyperdensity within intrahepatic bile ducts (arrow in A) and within the CBD (arrow in B) suggesting hemobilia.*

Follow-up imaging

- Low-grade injuries usually need no follow-up CT unless the clinical status demands it.
- In grade IV or V injuries, follow-up US is usually needed between 7 and 10 days after injury. CEUS improves accuracy where available. CT is kept for selected complicated cases.
- Pseudoaneurysms should be treated early, and angiographic embolisation is the modality of choice.

PEARLS

- The AAST 2018 liver OIS gives the final grade from the highest of the imaging, operative and pathology criteria. Multiple grade I or II injuries advance the grade to III.
- The 2018 update added MDCT vascular injury (pseudoaneurysm, AV fistula) and contained active bleeding at grade III. Active bleeding into the peritoneum is grade IV.
- Grade V is >75% lobar disruption or a juxtahepatic venous injury. Grade VI is avulsion.
- Prompt multiphase CT (arterial and portal phases) is the technique of choice for upper abdominal trauma.
- Delayed complications to remember are delayed haemorrhage, pseudoaneurysm, haemobilia, abscess, biloma and biliary peritonitis.
- Exam trap: the AAST scale does not grade biliary injury. A biloma or bile leak needs HIDA scintigraphy or MRCP.

185. Traumatic visceral vascular injuries — imaging and interventional radiology

ASKED 1× · 10-mark answer

Asked in: Oct 2024 · Paper II · Q9 (10 marks)

Q: Discuss the imaging findings of traumatic visceral vascular injuries. Discuss the role of interventional radiology in its management. [5+5]

SOURCE

GA V1 — Ch 36 Genitourinary Tract Trauma — §Grading of Renal Injury; Active Bleeding; Pseudoaneurysm — pp. 925, 930–931
GA V1 — Ch 23 The Liver and Spleen — §Hepatic Trauma — p. 641
GA V1 — Ch 10 Thoracic Trauma and Related Topics — §Acute Traumatic Aortic Injury — pp. 234–235
GA V2 — Ch 54 Imaging of Head Trauma — §Vascular Injury — pp. 1393–1394
AMP V1 — Ch 25 Urinary Tract Trauma — e.1035, e.1048
AMP V2 — Ch 116 Imaging in Abdominal Trauma — e.4560, e.4573, e.4574
[W1] RSNA RadioGraphics — Grading Abdominal Trauma: Changes in and Implications of the Revised 2018 AAST-OIS for the Spleen, Liver, and Kidney (AAST organ injury scaling, Kozar et al., 2018) — 2023 — https://pubs.rsna.org/doi/10.1148/rg.230040
[W2] WSES — Follow-up strategies for patients with splenic trauma managed non-operatively: the 2022 WSES consensus document — 2022 — https://link.springer.com/article/10.1186/s13017-022-00457-5

Imaging findings of traumatic visceral vascular injuries

Imaging approach

- **Multiphase CT** is the technique of choice for upper abdominal trauma.

  - **Unenhanced:** fresh thrombus is denser than normal blood, so its site points to the nearby bleeding source (sentinel clot).
  - **Arterial and portal venous phases** are mandatory to detect arterial injuries and subtle lacerations.
  - **Arterial phase** shows symmetry of renal enhancement, active bleeding and pseudoaneurysm. **Portal venous phase** shows the extent of parenchymal damage and separates active bleeding from pseudoaneurysm.
- **Single portal venous phase** (about 60–70 s) is often the only phase done. If it shows a contained vascular injury or extravasation, an immediate localised repeat phase confirms it.
  - A 5–10 min urographic delay is added if the kidney is injured.
  - Routine dual phase is not advocated because of radiation; the arterial phase is used mainly for displaced pelvic ring fractures and severe mechanisms.
- **Doppler US** and arterial-phase CT or MRI demonstrate larger arteriovenous shunts and enlarged supplying arteries.
- **Catheter angiography** is not a diagnostic test in renal trauma. It is reserved for therapeutic embolisation.

CT signs by type of vascular injury

Table 1: CT features of traumatic visceral vascular injury

Injury	Arterial phase	Portal venous / delayed	Significance
Active bleeding	Focal contrast pool, density like the aorta	Pool enlarges and stays dense; >80 HU and within 15 HU of an adjacent artery	Predicts need for embolisation or surgery
Pseudoaneurysm	Rounded or oval high-density focus	Becomes isodense; stays isodense to the aorta on delayed images	May rupture late or stay silent for years
AV fistula or shunt	Seen as an arteriovenous shunt with an enlarged supplying artery	–	A contained vascular injury
Devascularisation or infarct	Asymmetric or absent enhancement of the organ or segment	Parenchymal damage extent	Splenic laceration with >25% devascularisation is grade IV
Hilar avulsion or shattered organ	Non-enhancing fragments, hilar disruption	Perinephric or peritoneal blood	Grade V

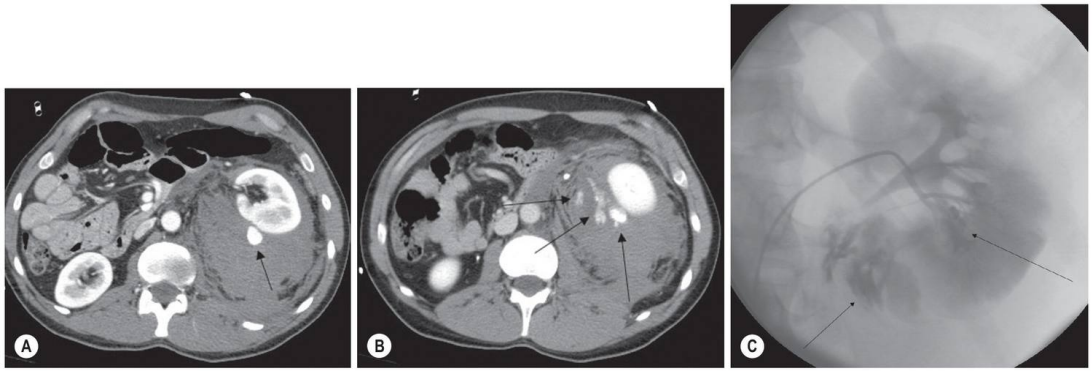

Fig. 36.14 — GA V1, p. 930. A 22-Year-Old Man Following a Motor Vehicle Collision. (A) Arterial-phase multidetector computed tomography image demonstrates a large left perinephric haemorrhage with an oval focus of high density adjacent to the posterior aspect of the mid-kidney (arrow). (B) Portal venous phase image at the level of the lower pole shows the focus has remained dense and increased in size (ar

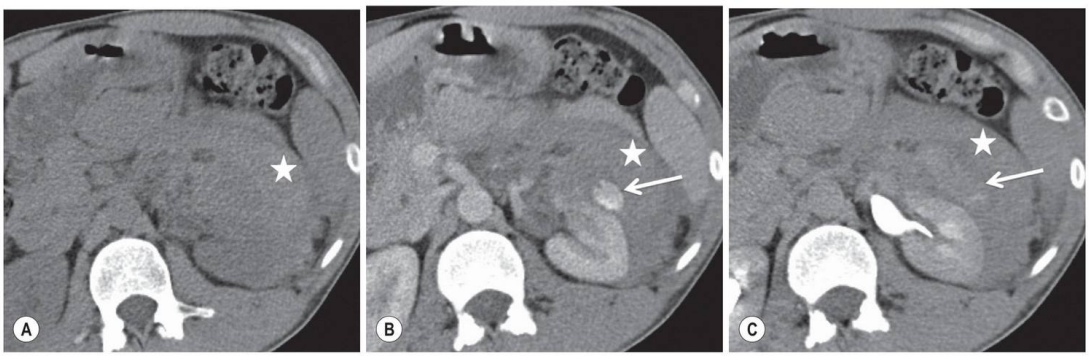

Fig. 36.15 — GA V1, p. 931. A 45-Year-Old Man Imaged Following a Stab Injury to His Left Flank. (A) Axial unenhanced multidetector computed tomography image shows a large left perinephric haematoma (asterisk). (B) Axial portal venous phase imaging demonstrates a high-density focus representing a pseudoaneurysm (arrow), which remains isodense to the aorta on delayed images (C).

Organ-specific findings

- **Kidney**
  - Active bleeding appears as a large perinephric haematoma with a dense focus that grows on the portal venous phase.
  - Pseudoaneurysms are commoner in penetrating than blunt trauma. They may present days later with haematuria or rupture, or stay asymptomatic for years.
  - **Discontinuity of Gerota fascia** has a PPV of 92% and NPV of 78% for needing embolisation.
  - A large subcapsular haematoma can cause hypertension (**Page kidney**).
- **Spleen**
  - The arterial phase shows vascular injury better, but heterogeneous arterial enhancement can mimic injury, so the portal venous phase must be reviewed.
  - A **delayed phase** separates laceration from cleft. Lacerations fill in from the periphery; clefts are unchanged and smooth.
  - The AAST scale ignored CT vascular injury. Marmery's modification put active bleeding, pseudoaneurysm or AV fistula and shattered spleen in grade IVa, and active intraperitoneal bleeding in IVb.
- **Liver**
  - Lacerations directly involving major vessel branches are rare but can cause life-threatening haemorrhage.
  - Later complications are ischaemia, necrosis, abscess, haemobilia, focal fibrosis, calcification and lobar or segmental atrophy.
  - Traumatic AV shunts can also occur.
- **Thoracic aorta (acute traumatic aortic injury)**
  - It is commonest at the isthmus, about 2 cm distal to the left subclavian origin.
  - **Direct CT signs** are intimal flap, pseudoaneurysm, contained rupture, abnormal contour and sudden calibre change (pseudocoarctation). MDCT sensitivity and specificity are about 98%.
  - Review **MPR**. Cardiac motion can mimic an intimal flap, and a ductus diverticulum is a pitfall.
  - Minor injuries (minimal aortic injury, intimal flap, pseudoaneurysm and rupture) form the **SVS grades I–IV**.

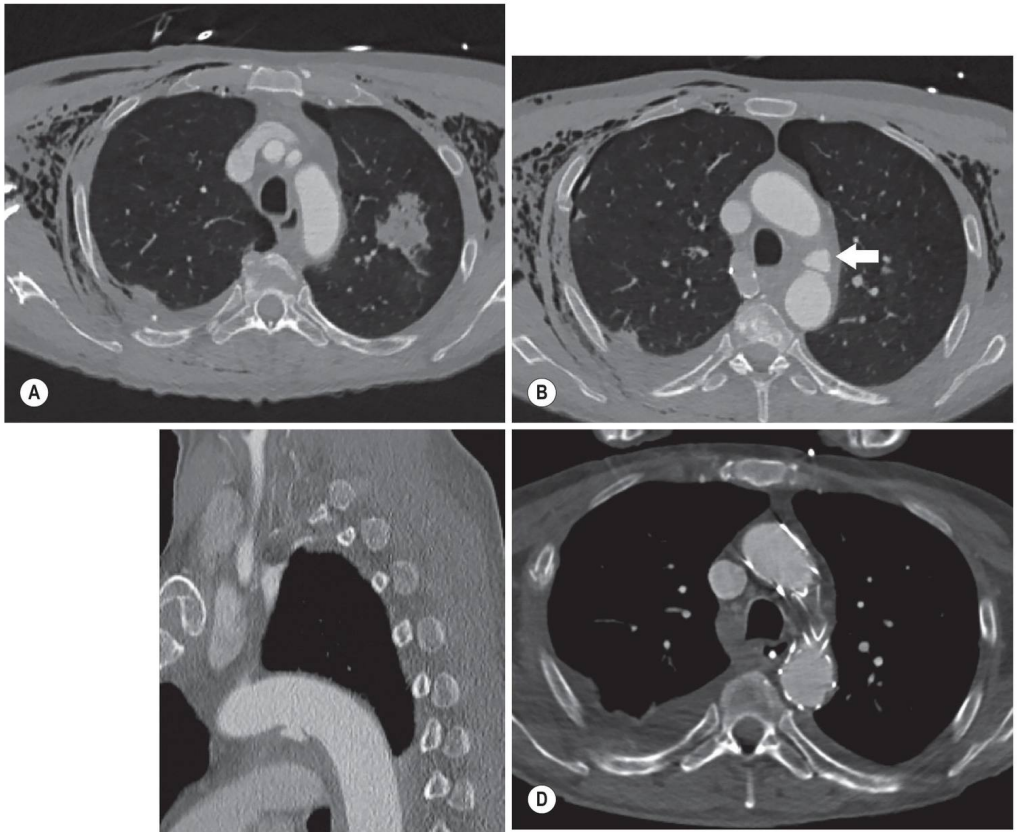

Fig. 10.4 *— GA V1, p. 235. Traumatic Aortic Injury. CT study showing mediatinal haematoma and lung contusion (A), trau- matic pseudoaneurysm in axial (arrow) (B) and sagittal (C) images. Subsequent study shows apprearance following endovascular treatment with a stent covering the defect (D).*

Grading of vascular injury (current AAST 2018 OIS)

- The final grade is the highest of the imaging, operative and pathology grades. The key change was adding MDCT vascular injury (pseudoaneurysm and AV fistula).

- **Liver:** grade III includes vascular injury or contained active bleeding. Grade IV is active bleeding extending into the peritoneum. Grade V is a juxtahepatic venous injury. Grade VI is avulsion.
- **Spleen:** grade IV is any splenic vascular injury or active bleeding within the capsule, or >25% devascularisation. Grade V is a shattered spleen, or vascular injury with bleeding beyond the spleen.

Table 2: Renal vascular injury grading — older book version versus current

Book (GA, 7th ed.; revised AAST 2011)	Current (AAST OIS, 2018)
Grade IV: segmental vein or artery injury; main renal artery or vein injury with contained haemorrhage	Grade III: vascular injury or active bleeding confined within the perirenal fascia
Grade V: hilar avulsion that devascularises the kidney	Grade IV: segmental artery or vein injury, segmental infarction, active bleeding beyond the perirenal fascia
Active bleeding, pseudoaneurysm and segmental infarction not classified	Grade V: shattered or devascularised kidney with bleeding, main vessel laceration, hilar avulsion

Role of interventional radiology

Patient selection

- IR serves the **haemodynamically stable** patient with a CT-proven vascular injury. Angiography confirms the injury and embolisation treats it.
- Active bleeding with haemodynamic instability may need surgical exploration.
- The only absolute indication for exploration or angioembolisation is life-threatening active haemorrhage.

Flowchart 1: Management of CT-detected visceral vascular injury

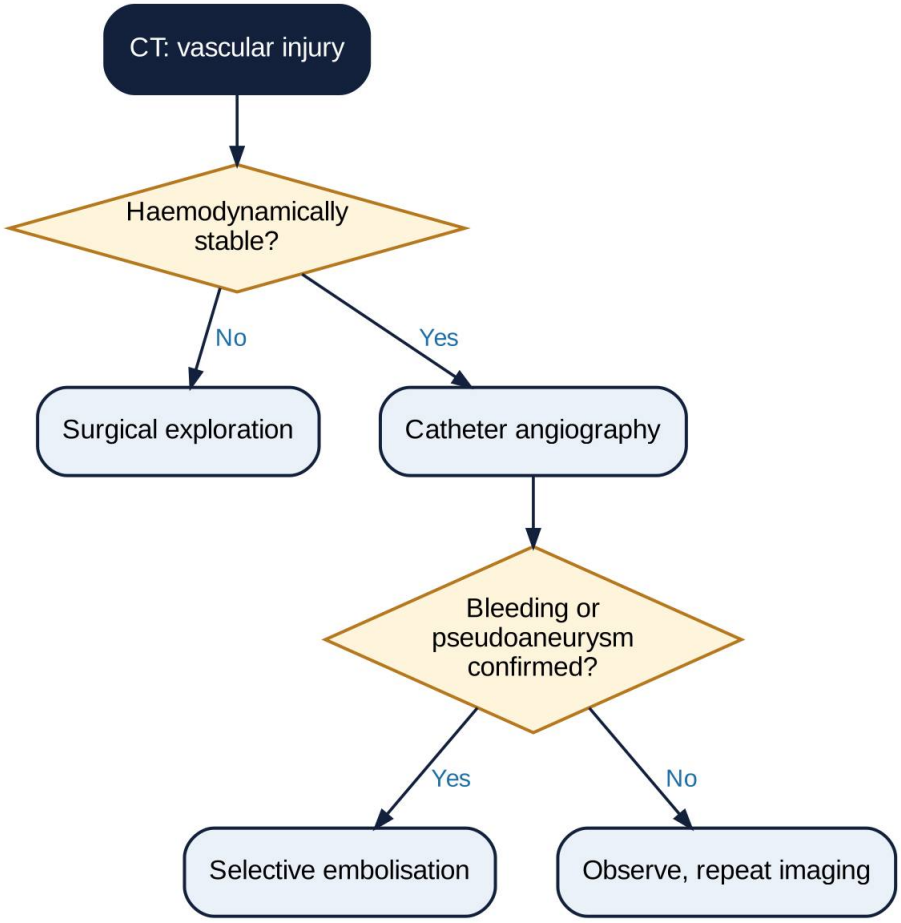

Indications by organ

Table 3: Embolisation indications

Organ	Indication for IR
Kidney	Post-traumatic pseudoaneurysm, AV fistula and ongoing haemorrhage in stable patients. Embolisation success is >90% with coils, Gelfoam or both
Spleen	Grade 4–5 injury, and active leak or pseudoaneurysm. Selected grade III with large haemoperitoneum and transient response to resuscitation
Liver	Angiography reserved for therapeutic embolisation after CT shows arterial injury
Thoracic aorta	Endovascular stent-graft repair. Grade III injuries benefit from early intervention
Carotid or vertebral	DSA for planned endovascular treatment, e.g. stenting a flow-limiting traumatic dissection

Splenic artery embolisation (SAE)

- It lowers splenic perfusion pressure by blocking the arterial supply.
- Collaterals from the pancreatic circulation prevent significant infarction, so splenic function is preserved.
- It reduces haematocrit drop, fluid needs and hospital stay.
- **WSES 2022:** in stable patients with a CT arterial blush, SAE is first-line irrespective of grade.
  - There is a low threshold for SAE in AAST III injuries without extravasation when non-operative-failure risk factors are present.
  - Angiography with possible SAE is suggested in all stable AAST IV–V injuries, even without a blush.

Renal embolisation

- It is selective: a segmental branch can be coiled to thrombose a pseudoaneurysm.
- Relative indications for operation are >50% parenchymal devitalisation, arterial thrombosis, and urinary extravasation uncontrolled by drainage or stenting.
- Main renal artery thrombosis: thrombolysis with stenting is possible if <2 h from injury or the patient has a solitary functioning kidney.
- **Follow-up:** repeat imaging of high-grade injuries with an excretory phase at 48–72 h detects missed leaks or vascular injury. Low-grade injuries need none unless the patient worsens.

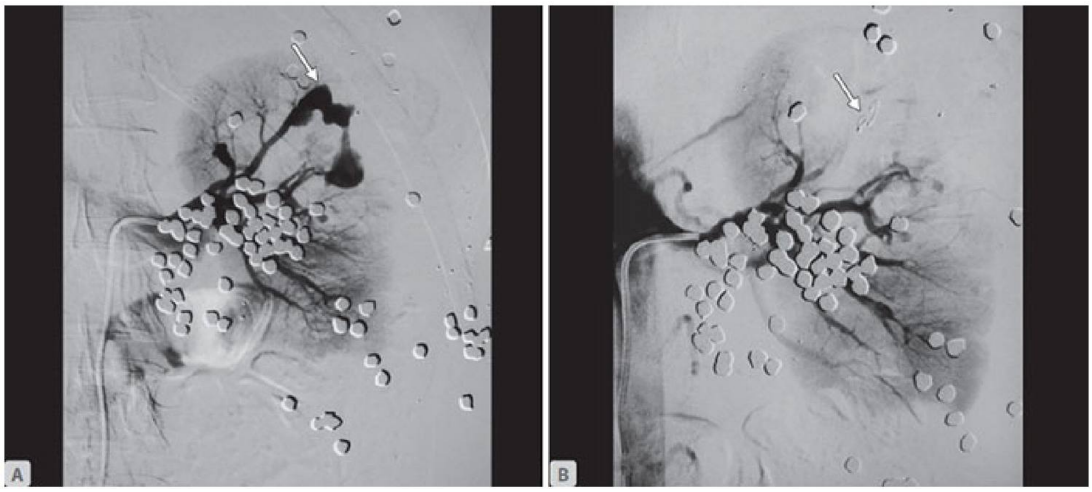

FIGS. 13A AND B *— AMP V1, e-book p. 1048. FIGS. 13A AND B: DSA image (A) of selective left renal artery injection in a patient injured with multiple pellets shows pseudoaneurysm formation with active bleed (arrow) in upper pole of left kidney. The involved upper polar segmental branch was selectively embolized with coil (arrow in B) resulting in thrombosis of pseudoaneurysm.*

Aortic and vascular adjuncts

- Endovascular repair has brought treatment mortality down to about 5–10%.
- Catheter angiography misses about 50% of minimal injuries, so it is no longer a diagnostic step. It is now done only as part of endovascular repair.
- Intravascular ultrasound is used by some centres for indeterminate lesions.
- Hybrid open and endovascular repair is possible in stable patients.

- Grade I SVS injuries are managed conservatively. Grade II injuries need repeat CT or MR aortography, with early intervention if they progress.

PEARLS

- Vascular injury on CT means a contrast pool that grows on the portal venous phase (active bleeding) or one that becomes isodense (pseudoaneurysm).
- Active bleeding is >80 HU and within 15 HU of an adjacent artery. Pseudoaneurysm washes out to isodense with the aorta.
- Always add a delayed or repeat phase if the single portal venous phase is suspicious.
- AAST 2018 now grades CT vascular injury; the older book scale for the kidney and the spleen did not.
- Embolisation is for the stable patient. Unstable patients with active bleeding need surgery.
- SAE is first-line for stable splenic blush; renal embolisation success is >90%.
- Exam trap: arterial-phase heterogeneous splenic enhancement mimics injury, and a cleft is not a laceration.

186. Renal trauma and haematuria after blunt trauma — approach, imaging and grading

ASKED 2× · 10-mark answer

Asked in: Dec 2020 · Paper III · Q10 (10 marks) · Dec 2022 · Paper II · Q5 (10 marks)

Q: Describe approach to a patient in renal trauma with a flow chart & discuss the role of imaging with grades of renal injury. [4+6]

Q: Discuss the imaging workup of a patient of blunt abdominal trauma presenting with hematuria. [10]

SOURCE

GA V1 — Ch 36 Genitourinary Tract Trauma — §Renal Trauma, Imaging Technique, Grading, CT Findings, Active Bleeding, Pseudoaneurysm — pp. 923–931
GA V2 — Ch 72 Imaging of the Kidneys, Urinary Tract and Pelvis in Children — §Trauma — p. 1883
AMP V1 — Ch 25 Urinary Tract Trauma — §Imaging Work-up, Radiological Findings — e.1032–e.1036
AMP V2 — Ch 116 Imaging in Abdominal Trauma — §CT cystography — e.4561
[W1] RSNA RadioGraphics (AAST OIS 2018 update for spleen, liver and kidney) — Grading Abdominal Trauma: Changes in and Implications of the Revised 2018 AAST-OIS — 2023 — https://pubs.rsna.org/doi/10.1148/rg.230040
[W2] WSES–AAST — Kidney and uro-trauma: WSES-AAST guidelines — World J Emerg Surg 2019;14:54 — https://pmc.ncbi.nlm.nih.gov/articles/PMC6886230/

Approach to a patient with renal trauma

- **Likelihood of injury:** about 10% of blunt and penetrating abdominal trauma involves the kidney. Almost 90% of renal injuries are blunt, mostly road traffic accidents.
- **Unstable patients:** Patients who are haemodynamically unstable and cannot be rapidly resuscitated usually go straight to surgery.
- **Stable patients:** the kidneys are imaged as part of a standard abdomen–pelvis CT.
- **Management follows grade and haemodynamic status.**

Flowchart 1: Approach to blunt renal trauma

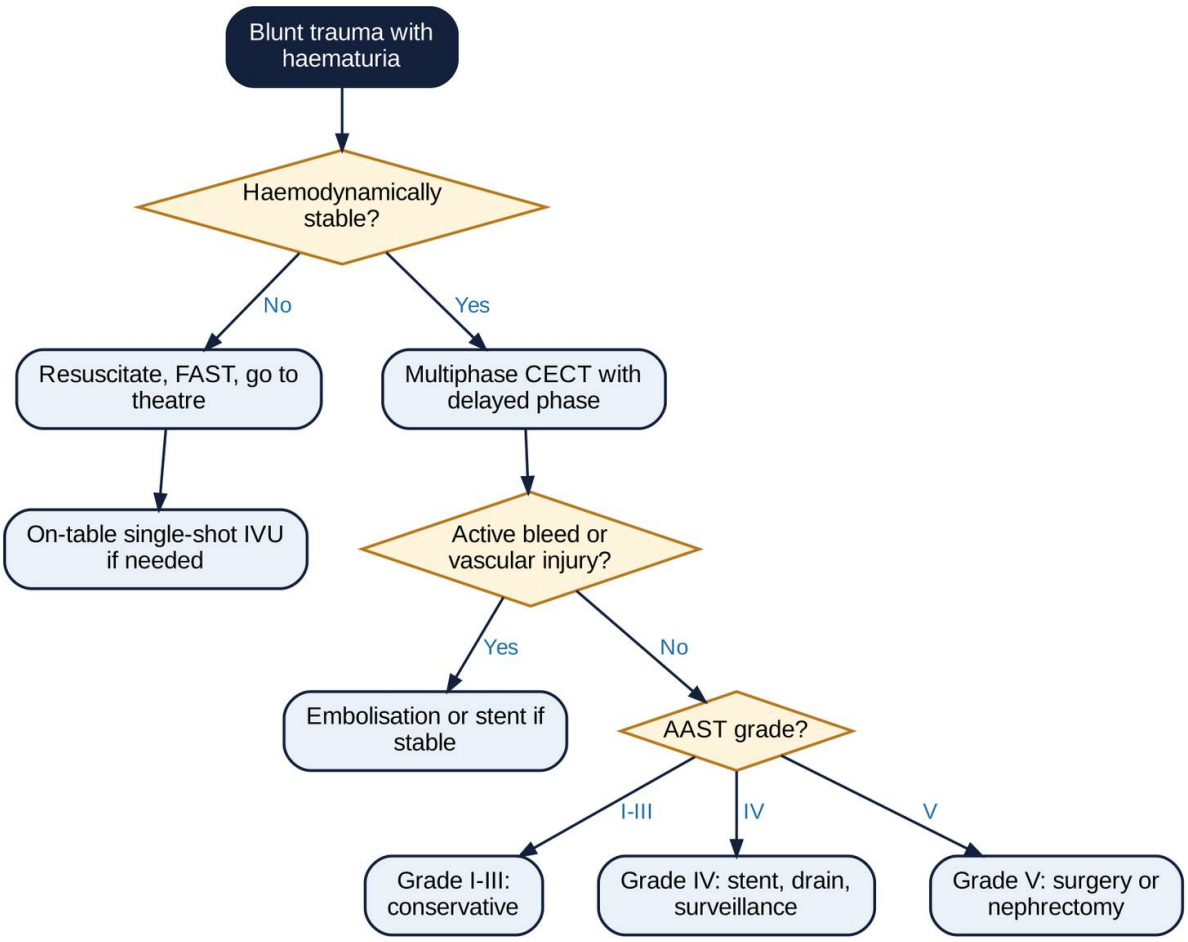

Imaging workup of blunt abdominal trauma with haematuria

Who to image

- **Haemodynamically stable with:** gross haematuria, a concerning mechanism of injury, or concerning examination findings.
- **Hypotensive:** systolic BP <90 mm Hg with microscopic haematuria.
- **Associated injuries:** flank soft-tissue contusion or haematoma, and lumbar spine, lower rib or transverse process fractures.
- **Haematuria can mislead:** it may be absent in vascular pedicle injury, ureteral tear and ureteropelvic disruption.
- **Children:** haematuria does not correlate with severity, so every child with haematuria after abdominal trauma should have renal imaging.
- **Suspect an underlying lesion** if the injury is out of proportion to the mechanism. Examples are angiomyolipoma, hydronephrosis, horseshoe or ectopic kidney, cyst, tumour and transplant.

Role of each modality

Table 1: Modality roles in renal trauma

Modality	Role	Limit
FAST/eFAST	Rapid yes/no answer on free fluid in the unstable patient	Poor sensitivity for renal trauma; retroperitoneum poorly assessed
CECT (MDCT)	Gold standard; assesses the upper and lower tracts and concurrent injuries	Radiation; transport of the patient
IVU	No longer has a role in acute GU trauma; tailored single-shot only in theatre or unstable patients	Insensitive for parenchymal injury
Angiography	Therapeutic only, not diagnostic	Invasive
MRI	Only if CT is contraindicated or unavailable	Long examination time
US (follow-up)	Follow-up of renal injury, especially in children	Operator-dependent

CT technique

- **GA whole-body protocol (128-slice MDCT):** unenhanced scan, then arterial phase from the lower neck to the proximal femurs.
- **Contrast:** 100 mL of 350 mg/mL iodinated contrast at 4 mL/s; scan triggered at 100 HU in the ascending aorta.
- **Portal venous phase:** abdomen and pelvis at 70 s.
- **Delayed phase:** at 5 and/or 10 min if renal injury is suspected, to show collecting-system extravasation. A reduced dose is adequate. AMP uses a 3–5 min delayed acquisition through the kidneys.
- **Arterial phase** shows enhancement symmetry, active bleeding and pseudoaneurysm.
- **Portal venous phase** shows the extent of parenchymal damage and separates active bleeding from pseudoaneurysm.
- **Bladder:** CT cystography is used for haematuria with no renal injury on CT, or with pelvic fracture. It uses 300–400 mL of 1:10 diluted contrast via a catheter.
- **A passively filled delayed phase is not a substitute for cystography.**

Grades of renal injury and role of imaging

- **Rule for grading:** a renal unit with more than one injury is classified by the higher grade.
- **The book's table is the 2011 revision:** it was based on Buckley and McAninch's review of 3580 renal injuries.
- **The current version is the AAST OIS 2018 update.** It adds MDCT vascular injury (pseudoaneurysm and AV fistula) and takes the highest of the imaging, operative and pathology grades.

Table 2: AAST renal injury grading — book version vs current

Grade	Book (GA, 7e; AAST 2011 revision)	Current (AAST OIS, 2018)
I	Subcapsular haematoma and/or contusion	Subcapsular haematoma and/or contusion, no laceration
II	Laceration <1 cm, cortex only; small perirenal haematoma in Gerota fascia	Perirenal haematoma confined to Gerota fascia, or laceration ≤1 cm without extravasation
III	Laceration >1 cm into medulla; haematoma in Gerota fascia	Laceration >1 cm without collecting-system rupture; vascular injury or active bleeding within the perirenal fascia
IV	Laceration into collecting system with extravasation; pelvis or PUJ disruption; segmental vessel injury; main vessel injury with contained haemorrhage	Collecting-system laceration with extravasation; pelvis laceration or PUJ disruption; segmental vessel injury; segmental infarct; active bleeding beyond the perirenal fascia
V	Shattered kidney; hilar avulsion with devascularisation	Shattered kidney; devascularised kidney with active bleeding; main vessel laceration or hilar avulsion

- **Bilateral injuries:** advance one grade, up to grade III.

CT features and management by grade

- **Grade I:**
  - A contusion is an ill-defined low-attenuation area with irregular margins; a striated nephrogram may be seen.
  - A subcapsular haematoma is a convex collection indenting the parenchyma, hyperdense when acute.

CLINICA
PUBLICATION

DNB EXIT EXAM · SOLVED PREVIOUS-YEAR QUESTION PAPERS

DNB Radiodiagnosis

Solved Previous-Year Questions

VOLUME IV

Neuro, Spine, Head and Neck and Musculoskeletal

Answers are written from six radiology textbooks — Grainger & Allison 7e, Rumack & Levine 6e, Chapman & Nakielny 7e, Christensen 4e, AIIMS-MAMC-PGI 3e and Core Radiology 2e — one lead book per question, with the chapter and pages named in each answer, and from current reporting systems, guidelines and Indian regulations found on official sites, listed in the Web-Sourced Facts Register.

REVIEWED BY

Dr Hemant Kumar
DNB Radiodiagnosis

Dr. Khusbo Singh
DNB Radiodiagnosis

UPDATED TILL OCTOBER 2026

CLINICA PUBLICATION
www.clinicapublication.com

Index

HOW TO USE

Each answer groups every year and paper the question was asked in and is written to the union of what those versions asked. The badge shows how often it was asked. The SOURCE box under each question names the textbook chapters and pages used and any current guideline or web source [W#]; every [W#] is also listed in the register at the end. Book images carry their own figure number and page; anatomy and diagram questions also carry a schematic exam diagram you can reproduce in 2–3 minutes. A lists the parts, B this volume question by question, C the high-yield topics (asked 3× or more).

A · Parts

Part 20 — Neuroradiology — brain	27 answers	9
Part 21 — Spine and spinal cord	8 answers	116
Part 22 — Head and neck	24 answers	153
Part 23 — Musculoskeletal radiology	30 answers	250

B · This volume, question by question

259. Acute ischaemic stroke — CT and MRI features, imaging algorithm and interventional radiology Asked in: Jun 2020 · Paper I · Q1 (10 marks) · Dec 2020 · Paper I · Q7 (10 marks) · Dec 2021 · Paper I · Q9(a) (5 marks) · Apr 2023 · Paper I · Q3 (10 marks)	4×	9
260. Subarachnoid haemorrhage — causes, subarachnoid spaces, imaging evaluation and endovascular treatment of aneurysm Asked in: Jun 2022 · Paper I · Q5 (10 marks) · Oct 2023 · Paper I · Q2 (10 marks) · Dec 2025 · Paper I · Q9 (10 marks)	3×	14
261. Intracranial aneurysms — sites, aetiology and the role of interventional radiology Asked in: Oct 2024 · Paper I · Q8 (10 marks)	1×	21
262. Intracerebral haemorrhage — MRI stages and their pathophysiological basis Asked in: Apr 2023 · Paper I · Q8(a) (5 marks)	1×	26
263. Cerebral venous thrombosis — clinical presentation and imaging Asked in: May 2024 · Paper I · Q2 (10 marks)	1×	28
264. Brain herniation — types, imaging features and complications Asked in: Dec 2022 · Paper I · Q2 (10 marks)	1×	34
265. Traumatic head injury — CT technique, types of injury and the role of MRI Asked in: Oct 2023 · Paper II · Q3 (10 marks)	1×	38
266. Intracranial tuberculosis — manifestations, pathology, CT and MRI Asked in: Dec 2021 · Paper I · Q1 (10 marks)	1×	44
267. Neuroimaging manifestations of COVID-19 Asked in: Apr 2023 · Paper I · Q4 (10 marks)	1×	48
268. Congenital TORCH infections — neuroimaging Asked in: Apr 2023 · Paper I · Q8(b) (5 marks)	1×	50
269. Ring-enhancing lesions in an adult — differential diagnosis Asked in: Dec 2025 · Paper I · Q8 (10 marks)	1×	52
270. CNS manifestations of HIV — imaging Asked in: Jun 2022 · Paper I · Q2 (10 marks) · Jun 2025 · Paper I · Q4 (10 marks)	2×	58
271. Suprasellar tumours — craniopharyngioma and differential diagnosis Asked in: Jun 2021 · Paper I · Q6 (10 marks) · Dec 2025 · Paper I · Q4 (10 marks)	2×	61
272. Sella turcica — radiological anatomy, masses in and around the sella and abnormal sellar shape Asked in: Dec 2021 · Paper I · Q7(a) (5 marks) · Oct 2024 · Paper IV · Q7 (10 marks)	2×	65
273. Pituitary adenoma — imaging Asked in: Jun 2025 · Paper I · Q2(b) (5 marks)	1×	69
274. Classification of CNS tumours in adults (WHO) Asked in: Jun 2025 · Paper I · Q2(a) (5 marks)	1×	72

275. Paediatric posterior fossa tumours — protocol and imaging of the commonest three Asked in: Dec 2020 · Paper I · Q6 (10 marks)	1×	74
276. Cerebellopontine angle — imaging anatomy and masses Asked in: May 2024 · Paper I · Q9 (10 marks)	1×	78
277. Epilepsy imaging — protocol, mesial temporal sclerosis, advanced MR and nuclear techniques Asked in: Dec 2020 · Paper I · Q10 (10 marks) · Dec 2022 · Paper I · Q5 (10 marks) · Dec 2025 · Paper I · Q10(a) (5 marks)	3×	83
278. Long-term epilepsy-associated tumours (LEATs) — differential diagnosis and imaging Asked in: Oct 2024 · Paper I · Q2 (10 marks)	1×	88
279. Neurocutaneous syndromes — overview and von Hippel–Lindau disease Asked in: Jun 2020 · Paper I · Q7 (10 marks)	1×	92
280. Sturge–Weber syndrome — imaging Asked in: Dec 2021 · Paper I · Q7(b) (5 marks)	1×	97
281. Neurofibromatosis type 2 — imaging Asked in: Dec 2021 · Paper I · Q9(b) (5 marks)	1×	99
282. Tuberous sclerosis — clinical presentation and multisystem imaging Asked in: May 2024 · Paper I · Q7 (10 marks)	1×	102
283. Hypoxic–ischaemic encephalopathy — imaging in term and preterm neonates Asked in: Jun 2021 · Paper I · Q1 (10 marks) · Dec 2022 · Paper I · Q9 (10 marks)	2×	105
284. Retrocerebellar cyst in a child — differential diagnosis Asked in: Dec 2022 · Paper I · Q8 (10 marks)	1×	110
285. Neuromyelitis optica — imaging Asked in: Dec 2025 · Paper I · Q10(b) (5 marks)	1×	113
286. Thoracolumbar spinal trauma — classification, patterns of vertebral injury and role of MRI Asked in: Jun 2020 · Paper I · Q5 (10 marks) · Dec 2025 · Paper II · Q3 (10 marks)	2×	116
287. Cervical spine injury — role of imaging and patterns of injury Asked in: Oct 2024 · Paper II · Q1 (10 marks)	1×	123
288. Osteoporotic versus metastatic vertebral collapse — risk factors and MRI differentiation Asked in: Jun 2021 · Paper I · Q3(b) (4 marks) · Oct 2023 · Paper I · Q1 (10 marks)	2×	128
289. Lumbar disc herniation — current nomenclature by type and location Asked in: Jun 2021 · Paper I · Q3(a) (6 marks)	1×	133
290. Spinal nerve sheath tumours — types and imaging Asked in: Jun 2022 · Paper I · Q9 (10 marks)	1×	136
291. Spinal canal neoplasms and intramedullary tumours — imaging and differential diagnosis Asked in: Apr 2023 · Paper I · Q9 (10 marks) · Dec 2025 · Paper I · Q6 (10 marks)	2×	140
292. Paediatric spinal cord neoplasms and intradural extramedullary masses in a child Asked in: Oct 2023 · Paper I · Q10 (10 marks)	1×	145
293. Spinal dysraphism — types and imaging of open dysraphism Asked in: Dec 2022 · Paper I · Q1 (10 marks)	1×	150
294. Post-traumatic carotid–cavernous fistula — diagnosis and endovascular treatment Asked in: Jun 2020 · Paper I · Q2 (10 marks)	1×	153
295. Proptosis — causes and the role of imaging Asked in: Dec 2021 · Paper I · Q6 (10 marks) · Jun 2025 · Paper I · Q7 (10 marks)	2×	157
296. Extraconal orbital mass in a child — differential diagnosis Asked in: Dec 2022 · Paper I · Q6 (10 marks)	1×	163
297. Ocular ultrasound anatomy and idiopathic orbital inflammation Asked in: Apr 2023 · Paper I · Q2 (10 marks)	1×	167
298. Lacrimal gland lesions — pathologies and imaging Asked in: May 2024 · Paper I · Q1 (10 marks)	1×	170
299. Leukocoria in a child — causes and imaging Asked in: Jun 2022 · Paper I · Q3 (10 marks)	1×	173

300. Sensorineural hearing loss in a child — inner ear anatomy and imaging work-up Asked in: Jun 2020 · Paper I · Q8 (10 marks) · Oct 2023 · Paper I · Q8 (10 marks) · Oct 2024 · Paper I · Q5 (10 marks)	3×	177
301. Otosclerosis — imaging Asked in: Dec 2025 · Paper I · Q3(b) (5 marks)	1×	181
302. Central skull base anatomy and imaging in CSF rhinorrhoea Asked in: Jun 2021 · Paper I · Q10 (10 marks)	1×	184
303. Paranasal sinuses — FESS protocol, anatomical landmarks and variants, and Aspergillus sinusitis Asked in: Dec 2020 · Paper I · Q8 (10 marks)	1×	190
304. Rhino-orbito-cerebral mucormycosis — risk factors and imaging Asked in: May 2024 · Paper I · Q4 (10 marks)	1×	193
305. Juvenile nasopharyngeal angiofibroma — imaging and preoperative embolisation Asked in: Oct 2023 · Paper I · Q6 (10 marks) · Dec 2025 · Paper I · Q3(a) (5 marks)	2×	196
306. Suprahyoid neck spaces and the masticator space Asked in: Jun 2021 · Paper I · Q5 (10 marks) · Dec 2022 · Paper I · Q3 (10 marks)	2×	200
307. Infrahyoid neck spaces and carotid space pathologies Asked in: Oct 2023 · Paper I · Q7 (10 marks)	1×	205
308. Radiological anatomy of the neck spaces Asked in: Dec 2025 · Paper IV · Q8(b) (5 marks)	1×	209
309. Midline neck masses in a child and thyroglossal duct cyst Asked in: Dec 2021 · Paper I · Q2 (10 marks)	1×	212
310. Branchial cleft cysts — types and imaging Asked in: Apr 2023 · Paper I · Q6 (10 marks)	1×	215
311. Perineural spread of head and neck malignancy — imaging Asked in: Oct 2024 · Paper I · Q7 (10 marks)	1×	218
312. Carcinoma base of tongue — MRI and the retromolar trigone Asked in: Dec 2025 · Paper I · Q7 (10 marks)	1×	221
313. Salivary gland tumours — classification and imaging Asked in: Jun 2022 · Paper I · Q4 (10 marks)	1×	224
314. Thyroid nodule — ultrasound evaluation and TI-RADS Asked in: Dec 2020 · Paper I · Q2 (10 marks) · Apr 2023 · Paper I · Q10 (10 marks) · May 2024 · Paper I · Q8 (10 marks)	3×	229
315. Malignant lesions of the thyroid — imaging Asked in: Jun 2022 · Paper I · Q7 (10 marks)	1×	235
316. Cystic lesions of the jaw — imaging Asked in: Jun 2022 · Paper I · Q10 (10 marks)	1×	240
317. Temporomandibular joint — MRI anatomy and common disorders Asked in: Jun 2025 · Paper I · Q1 (10 marks)	1×	244
318. Painful swelling of the proximal arm in an adolescent — differential diagnosis and role of imaging Asked in: Jun 2020 · Paper I · Q10 (10 marks)	1×	250
319. Ewing sarcoma — radiographic and imaging features Asked in: Dec 2021 · Paper I · Q5(b) (5 marks) · Dec 2025 · Paper I · Q1(b) (5 marks)	2×	255
320. Bone-forming tumours and osteosarcoma — types, radiography and MRI Asked in: Apr 2023 · Paper I · Q1 (10 marks) · Oct 2023 · Paper I · Q5 (10 marks)	2×	257
321. Myositis ossificans — imaging and differential diagnosis Asked in: Oct 2024 · Paper I · Q9 (10 marks)	1×	262
322. Soft-tissue tumours of the extremities — classification and the MRI report Asked in: Jun 2025 · Paper I · Q6 (10 marks)	1×	265
323. Skeletal changes in leukaemia and haemolytic anaemia Asked in: Jun 2022 · Paper I · Q6 (10 marks) · Jun 2025 · Paper I · Q8 (10 marks)	2×	270
324. Multiple myeloma — imaging and differentiation from metastases Asked in: Jun 2025 · Paper I · Q3 (10 marks)	1×	275

325. Hyperparathyroidism — types, skeletal radiography, renal osteodystrophy and primary vs secondary Asked in: Jun 2020 · Paper I · Q3 (10 marks) · Jun 2021 · Paper I · Q2(a) (5 marks) · Jun 2025 · Paper I · Q10 (10 marks)	3×	279
326. Biochemically proven hyperparathyroidism — imaging work-up and 4D CT technique Asked in: Jun 2021 · Paper I · Q2(b) (5 marks) · Oct 2024 · Paper I · Q6 (10 marks)	2×	284
327. Rickets and osteomalacia — radiographic features Asked in: Dec 2021 · Paper I · Q10(b) (5 marks) · Apr 2023 · Paper I · Q7 (10 marks) · Dec 2025 · Paper I · Q1(a) (5 marks)	3×	290
328. Paget disease of bone — sites, imaging and differential diagnosis Asked in: May 2024 · Paper I · Q6 (10 marks)	1×	295
329. Diffuse hyperostosis of the skull — causes and radiology of two Asked in: Dec 2021 · Paper I · Q3 (10 marks)	1×	299
330. Hypertrophic osteoarthropathy — causes, radiography and differential diagnosis Asked in: Oct 2023 · Paper I · Q4 (10 marks)	1×	301
331. Cleidocranial dysplasia — radiographic features Asked in: Dec 2021 · Paper I · Q10(a) (5 marks)	1×	303
332. Painful hip or limp in a child — causes, imaging evaluation and features Asked in: Jun 2020 · Paper I · Q6 (10 marks) · Jun 2022 · Paper I · Q1 (10 marks)	2×	305
333. Perthes disease — radiographic findings Asked in: Dec 2021 · Paper I · Q5(a) (5 marks)	1×	309
334. Developmental dysplasia of the hip — risk factors, radiography and ultrasound Asked in: Dec 2022 · Paper I · Q7 (10 marks)	1×	311
335. Rheumatoid arthritis — US, MRI, multisystem features and differentiation from erosive osteoarthritis Asked in: Jun 2021 · Paper I · Q8 (10 marks) · Oct 2023 · Paper I · Q9 (10 marks)	2×	315
336. Non-infectious arthritis of large joints — imaging and diagnostic algorithm Asked in: May 2024 · Paper I · Q3 (10 marks)	1×	318
337. Ankylosing spondylitis — imaging and differential diagnosis Asked in: May 2024 · Paper I · Q10 (10 marks) · Oct 2024 · Paper I · Q10 (10 marks)	2×	322
338. Synovial disorders of the knee including lipoma arborescens — imaging and differential diagnosis Asked in: Dec 2020 · Paper I · Q3 (10 marks) · Dec 2025 · Paper I · Q2 (10 marks)	2×	327
339. Internal derangement of the knee — MR protocol, cruciate ligaments and ACL tear Asked in: Dec 2021 · Paper I · Q8 (10 marks) · Jun 2025 · Paper I · Q9 (10 marks)	2×	330
340. Meniscal tears — types, MRI findings and role of MR arthrography Asked in: Jun 2022 · Paper I · Q8 (10 marks) · Oct 2024 · Paper I · Q3 (10 marks)	2×	335
341. Imaging anatomy of the ligaments around the knee Asked in: Jun 2021 · Paper I · Q4(a) (5 marks)	1×	340
342. Cartilage imaging techniques and osteochondral lesions Asked in: Jun 2021 · Paper I · Q4(b) (5 marks) · Dec 2021 · Paper IV · Q4 (10 marks) · Dec 2025 · Paper IV · Q5(a) (5 marks)	3×	342
343. Recurrent shoulder dislocation — radiography, MRI and MR arthrography Asked in: Jun 2021 · Paper I · Q9 (10 marks) · Dec 2022 · Paper I · Q4 (10 marks)	2×	346
344. Ultrasound of the rotator cuff — technique, findings and limitations Asked in: Oct 2023 · Paper I · Q3 (10 marks)	1×	350
345. Femoroacetabular impingement — aetiology, radiography and MRI Asked in: Dec 2020 · Paper I · Q5 (10 marks)	1×	356
346. Avascular necrosis of the hip — pathogenesis and imaging Asked in: Jun 2025 · Paper I · Q5 (10 marks)	1×	360
347. Ankle ligaments — radiological anatomy and MR sequences and planes Asked in: Dec 2020 · Paper I · Q9 (10 marks)	1×	365

C · High-yield list — whole book (asked 3× or more)

145. Ischaemic heart disease — cardiac MRI, viability, nuclear imaging and MDCT	5×	Vol II, p. 193
152. Plain radiograph in rheumatic and mitral valve disease and left atrial enlargement	5×	Vol II, p. 223

1. X-ray tube — construction, X-ray production and tube failure	4×	Vol I, p. 10
13. Dual-energy CT — principle, acquisition methods and applications including pulmonary	4×	Vol I, p. 45
44. Iodinated contrast media — classification, adverse reactions and management including emergency drugs and anaphylaxis	4×	Vol I, p. 149
74. Breast MRI — indications, technique, advantages, limitations, non-mass enhancement and benign vs malignant	4×	Vol I, p. 240
94. Embolic agents — classification, advantages, disadvantages and clinical applications	4×	Vol I, p. 315
126. Mediastinal compartments (ITMIG), anterior mediastinal masses and thymoma	4×	Vol II, p. 115
158. Acute mesenteric ischaemia — causes, imaging and endovascular management	4×	Vol II, p. 246
233. Ectopic pregnancy and first-trimester bleeding — ultrasound, algorithm and mimics	4×	Vol III, p. 225
237. Fetal growth restriction — ultrasound and Doppler (uterine artery, umbilical artery, MCA, ductus venosus)	4×	Vol III, p. 240
259. Acute ischaemic stroke — CT and MRI features, imaging algorithm and interventional radiology	4×	9
8. Computed radiography and digital radiography — principles, advantages and disadvantages	3×	Vol I, p. 30
14. CT dose — CTDIvol, DLP and dose reduction in CT and radiography	3×	Vol I, p. 50
22. Colour Doppler — principle, Nyquist limit and artefacts and their prevention	3×	Vol I, p. 76
23. Ultrasound elastography — principles, techniques and applications including diffuse liver disease	3×	Vol I, p. 81
31. MRI artefacts, including motion artefacts and their reduction	3×	Vol I, p. 106
34. MRI safety — hazards, zoning of the MRI facility and safety considerations	3×	Vol I, p. 115
38. MR angiography — time-of-flight and phase-contrast principles, applications and pitfalls	3×	Vol I, p. 131
49. Ultrasound contrast agents — composition, generations, mechanism, applications, advantages and limitations	3×	Vol I, p. 169
51. Radiation protection — cardinal principles and protection of staff, patients and public	3×	Vol I, p. 176
56. Thermoluminescent dosimeter (TLD) badge — principles and uses	3×	Vol I, p. 188
70. Artificial intelligence in radiology	3×	Vol I, p. 226
82. Acute aortic syndrome and aortic dissection — classification, CT angiography and management	3×	Vol I, p. 266
86. Peripheral arterial disease — imaging modalities, CTA and MRA technique, and Doppler findings	3×	Vol I, p. 286
88. Renal artery stenosis — US, Doppler, MR angiography and intervention	3×	Vol I, p. 295
90. Varicose veins and venous incompetence — Doppler and interventional treatment	3×	Vol I, p. 301
92. Peripheral vascular malformations — diagnostic approach, Doppler and MRI, and interventional management	3×	Vol I, p. 308
95. Radiofrequency ablation — principle, indications, contraindications, complications and applications	3×	Vol I, p. 319
108. Acute pulmonary thromboembolism — pathophysiology, CT pulmonary angiography and imaging findings	3×	Vol II, p. 36
114. Haemoptysis — causes, imaging and interventional radiology	3×	Vol II, p. 59
117. Secondary pulmonary lobule, HRCT patterns of interstitial lung disease and usual interstitial pneumonia	3×	Vol II, p. 73
125. Cystic and cavitating lung lesions on CT — differential diagnosis	3×	Vol II, p. 111
137. Diaphragm — anatomy and traumatic injury on radiograph, US, CT and MRI; hernia vs eventration	3×	Vol II, p. 159
149. Congenital heart disease on the plain chest radiograph	3×	Vol II, p. 212

190. Segmental anatomy of the liver, triple-phase CT and imaging of hepatocellular carcinoma	3×	Vol III, p. 42
191. LI-RADS — categories, major and ancillary features, settings of use and role in management	3×	Vol III, p. 46
197. Budd–Chiari syndrome — causes, imaging, Doppler and interventional management	3×	Vol III, p. 70
206. Neonatal cholestasis and biliary atresia — US, MRI and scintigraphy	3×	Vol III, p. 102
207. Acute pancreatitis — radiography, CT and MRI	3×	Vol III, p. 108
208. Groove pancreatitis and mass-forming pancreatitis vs pancreatic adenocarcinoma	3×	Vol III, p. 111
210. Cystic pancreatic neoplasms — classification, imaging and side-branch IPMN	3×	Vol III, p. 121
216. Bosniak classification of renal cysts (version 2019) — criteria, significance and drawbacks	3×	Vol III, p. 146
217. Renal transplant — donor work-up, graft dysfunction and complications on US, Doppler and scintigraphy	3×	Vol III, p. 150
223. Carcinoma bladder — TNM/T staging with diagram, multiparametric MRI and VI-RADS	3×	Vol III, p. 175
228. Erectile dysfunction — penile Doppler technique, findings and limitations	3×	Vol III, p. 202
241. Placenta accreta spectrum and placental variants — US and MRI	3×	Vol III, p. 261
246. Acute pelvic pain in a young woman and ovarian torsion — causes and imaging	3×	Vol III, p. 285
249. Postmenopausal bleeding and endometrial carcinoma — imaging, differential diagnosis and staging	3×	Vol III, p. 301
260. Subarachnoid haemorrhage — causes, subarachnoid spaces, imaging evaluation and endovascular treatment of aneurysm	3×	14
277. Epilepsy imaging — protocol, mesial temporal sclerosis, advanced MR and nuclear techniques	3×	83
300. Sensorineural hearing loss in a child — inner ear anatomy and imaging work-up	3×	177
314. Thyroid nodule — ultrasound evaluation and TI-RADS	3×	229
325. Hyperparathyroidism — types, skeletal radiography, renal osteodystrophy and primary vs secondary	3×	279
327. Rickets and osteomalacia — radiographic features	3×	290
342. Cartilage imaging techniques and osteochondral lesions	3×	342

PART 20

Neuroradiology — brain

259. Acute ischaemic stroke — CT and MRI features, imaging algorithm and interventional radiology

ASKED 4× · 10-mark answer

Asked in: Jun 2020 · Paper I · Q1 (10 marks) · Dec 2020 · Paper I · Q7 (10 marks) · Dec 2021 · Paper I · Q9(a) (5 marks) · Apr 2023 · Paper I · Q3 (10 marks)

Q: Discuss in brief, the salient CT and MRI features in an acute ischemic stroke patient arriving to the hospital within 6 hours of onset. Suggest an algorithm based approach for confirmation of diagnosis and guiding the management of such a patient. [5+5]

Q: Discuss in brief the salient CT and MRI features in an acute ischemic stroke patient arriving to the hospital within 6 hours of onset. Suggest an algorithm based approach for confirmation of diagnosis and guiding the management of such a patient. [5+5]

Q: Enumerate: CT findings in case of ischemic stroke. [5]

Q: A 30-year-old man is brought to the emergency department with symptoms of acute stroke with onset 1 hour back. Discuss the imaging evaluation in such a case. Describe the role of interventional radiology in acute ischemic stroke. [6+4]

SOURCE

GA V2 — Ch 56 Neurovascular Diseases — §Stroke (Imaging strategies, CT signs, perfusion, MRI, multimodal platforms) — pp. 1441–1455
AMP V4 — Ch 188 Imaging and Interventions in Cerebral Ischemia — §Intra-arterial Therapy; Acute Stroke Imaging Protocol — e.7447–e.7449
[W1] Thomalla et al. — WAKE-UP trial, NEJM 2018;379:611–622 — 2018 — https://www.nejm.org/doi/full/10.1056/NEJMoa1804355
[W2] AHA/ASA — 2026 Guideline for the Early Management of Patients With Acute Ischemic Stroke, Stroke 2026;57:e316–e436 — 2026 — https://www.ahajournals.org/doi/10.1161/STR.0000000000000513
[W3] Indian College of Radiology and Imaging — Consensus Guidelines for the Early Management of Patients with Acute Ischemic Stroke: Imaging and Intervention — https://pmc.ncbi.nlm.nih.gov/articles/PMC8448212/
[W4] Nogueira et al. — DAWN trial, NEJM 2018;378:11–21 — 2018 — https://www.nejm.org/doi/full/10.1056/NEJMoa1706442

Salient CT and MRI features within 6 hours of onset

Non-contrast CT (NECT)

- NECT is the first-line test. It is rapid, accessible, simple and safe.
- Aims of NECT:
  - Exclude haemorrhage.
  - Exclude a non-vascular mimic, which accounts for about 30% of stroke-like presentations.
  - Assess infarct volume and ASPECTS.
  - Look for a hyperdense vessel.
- CT findings to enumerate in early ischaemic stroke:
  - **Hyperdense artery sign**: the earliest detectable change. It is caused by fresh thrombus, and thrombus may disperse so the sign is not always present.
  - **Sylvian fissure "dot" sign**: thrombus in an MCA branch within the fissure. It has a better prognosis than a proximal MCA or terminal ICA dense vessel.
  - Basilar artery hyperdensity in "top of basilar" syndrome.
  - Reduced grey-matter density with loss of grey–white differentiation, from cytotoxic oedema.
  - Loss of clarity of the lentiform nucleus margins and of the insular cortex.
  - Brain swelling with sulcal effacement.
  - Hypodensity over more than one-third of the MCA territory. IV thrombolysis is contraindicated at this extent, and above 50% mortality is high.
- Sensitivity is limited. NECT shows no convincing parenchymal change in 50–60% of cases within 2 hours. Reported sensitivity is 30% at 3 hours and 60% at 24 hours.
- The **stroke window** (W 35 / L 35) improves detection of subtle grey-matter hypodensity.

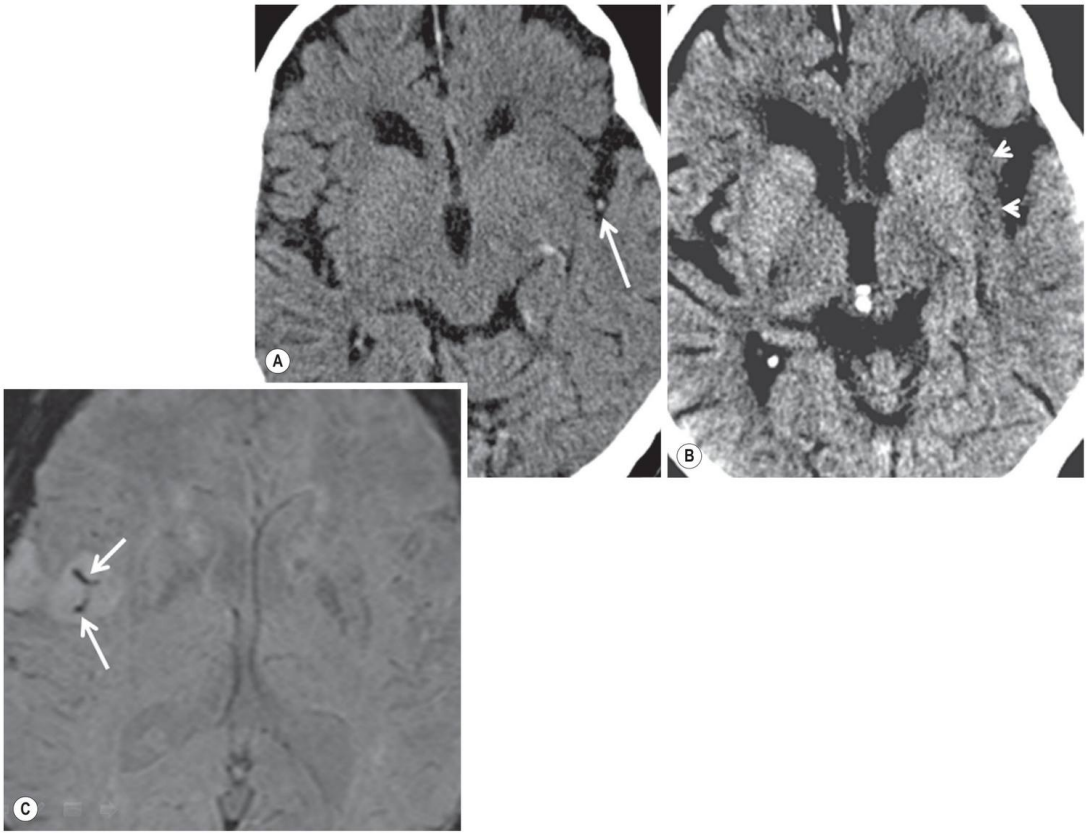

Fig. 56.5 — GA V2, p. 1446. Sylvian 'Dot' Sign. (A) There is thrombus within an M2 division of the left middle cerebral artery (MCA)—shown as a hyperdense dot in the left Sylvian fissure (white arrow). This caused by an acute left MCA territory infarct involving the left insula with loss of conspicuity of the cortex. This is made more conspicuous by adjusting the window settings to W = 35, L = 35: the 'st

- **ASPECTS**:
  - Two axial slices are scored: basal ganglia/internal capsule level, and the upper margin of the lateral ventricular bodies.
  - Ten regions are scored: four deep and six cortical (M1–M6).
  - The score starts at 10 and 1 point is deducted per involved region.
  - A score below 7 implies infarct greater than one-third of the MCA territory.

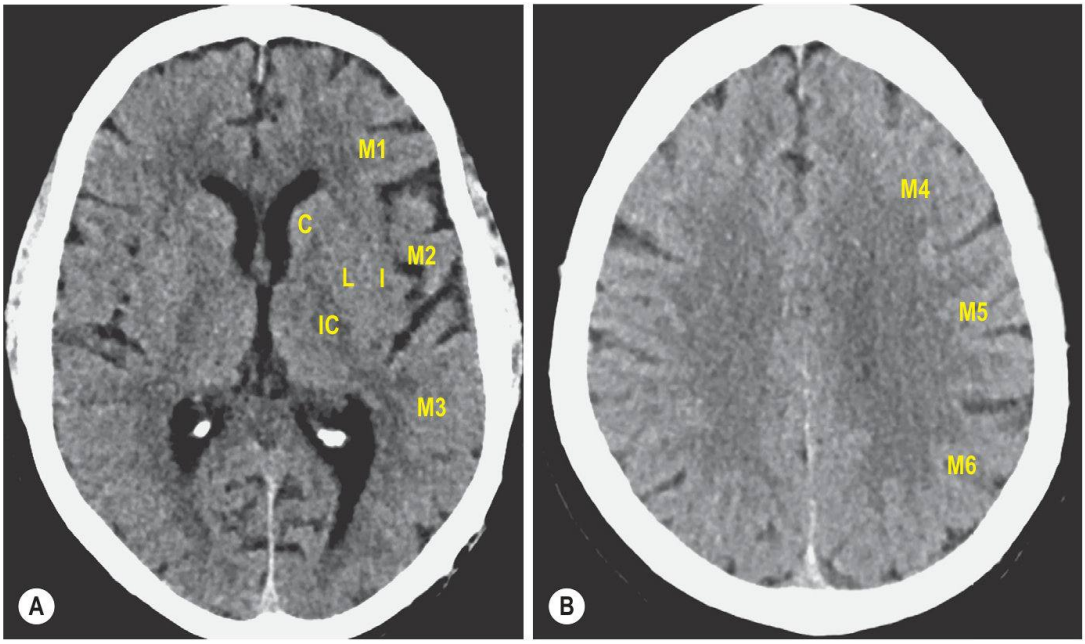

Fig. 56.7 — GA V2, p. 1447. Alberta Stroke Program Early Computed Tomography Score (ASPECTS) for Acute Ischaemic Change on Computed Tomography. (A) Slice at the level of the basal ganglia. C, Caudate nucleus; L, lentiform nucleus; IC, internal capsule; M1, M2 and M3, middle cerebral artery (MCA) territory at the level of the ganglionic nuclei. (B) M4, M5 and M6, MCA territory at the level above the gangli

CT angiography and CT perfusion

- **CTA** from the aortic arch to the circle of Willis (about 1 mm slices) identifies the large vessel occlusion (LVO). The hyperdense vessel sign alone misses some LVOs.
- CTA also shows neck embolic sources and dissection.
- CTA-source images read in the stroke window approximate CBV maps. Low density marks the core.
- **CT perfusion (CTP)**:
  - Core is thresholded CBF, usually a 70–85% reduction relative to the normal side.
  - Penumbra is **Tmax >6 s**. Delay-corrected MTT at 145% of the normal side is another marker.
  - **Mismatch** means penumbra at least 20% larger than the core.
  - A core volume above 70 mL predicts a poor outcome regardless of recanalisation.
  - A matched defect (core with no or small penumbra) carries reduced reperfusion benefit.

MRI

- **DWI** is the most sensitive and specific sequence. Hyperintensity appears within about 5 minutes of onset.
- Restricted diffusion is DWI-bright and **ADC-dark**. DWI must be read with the ADC map.

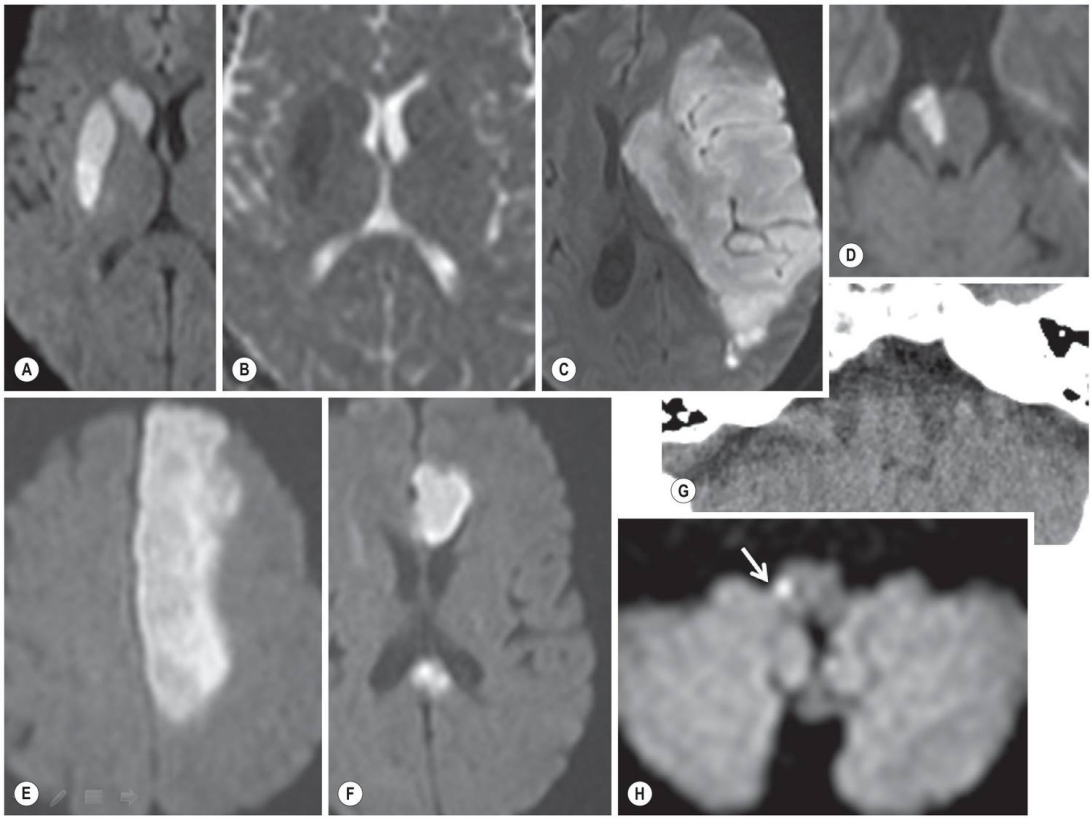

Fig. 56.9 *— GA V2, p. 1449. Acute Territorial Infarcts on Diffusion-Weighted Imaging. Acute right-sided striatal infarct with hyperintensity on diffusion-weighted imaging (DWI) (A) and hypointensity on apparent diffusion coefficient (B). Other acute infarcts involving the entire left middle cerebral artery (C) and left anterior cerebral artery (E and F) territories. Note the involvement of the left side o*

- DWI lesions are almost always irreversible. A small rim may reverse after early recanalisation.
- T2 and FLAIR changes are often absent or subtle before 3 hours.
- **FLAIR vascular hyperintensity** in a patent vessel indicates slow flow, and may be seen while the parenchyma is still normal.
- Loss of the arterial flow void indicates thrombus.
- **SWI/GRE**:
  - GRE has sensitivity for acute haemorrhage equivalent or superior to CT, and SWI enhances it further.
  - SWI shows thrombus as a blooming, hypointense, serpiginous vessel.
- **PWI** uses dynamic susceptibility contrast. MTT, CBF and TTP define the penumbra, and DWI defines the core.
- **MRA (TOF/CE-MRA)** shows the occlusion.
- **DWI–FLAIR mismatch** (wake-up or unknown onset):

- Tissue infarcted for under 3 hours is negative or only subtly abnormal on FLAIR. Tissue infarcted for over 4.5 hours is usually hyperintense.
- Trial pattern: DWI lesion without parenchymal FLAIR hyperintensity suggests onset within about 4.5 h.

Table 1: Key CT and MRI signs in the first 6 hours

Sign	Modality	Appearance	Significance
Hyperdense MCA/basilar	NECT	Bright thrombus in vessel	Earliest sign; LVO
Dot sign	NECT	Dense dot in Sylvian fissure	M2 thrombus
Insular/lentiform loss	NECT	Blurred margins	Early MCA infarct
Restricted diffusion	DWI/ADC	DWI bright, ADC dark	Core, from 5 min
Blooming vessel	SWI	Hypointense serpiginous vessel	Intraluminal thrombus
Tmax >6 s	CTP/PWI	Delay map	Penumbra

Imaging evaluation and algorithm (onset 1 hour back)

- CT remains the standard first investigation because of its availability, speed and sensitivity to haemorrhage.
- Emergent brain and vascular imaging is COR 1, LOE A. Adjunctive CTP or MRI is COR 2a when immediately available.
- Urgent neuroimaging before any specific treatment is the Indian consensus (class I, level A).
- A multimodal CT protocol (NECT + CTA + CTP) takes 3–5 min to acquire and 13–17 min in total. A multimodal MRI protocol takes 20–30 min in total.

Flowchart 1: Imaging algorithm for acute ischaemic stroke presenting within 6 hours

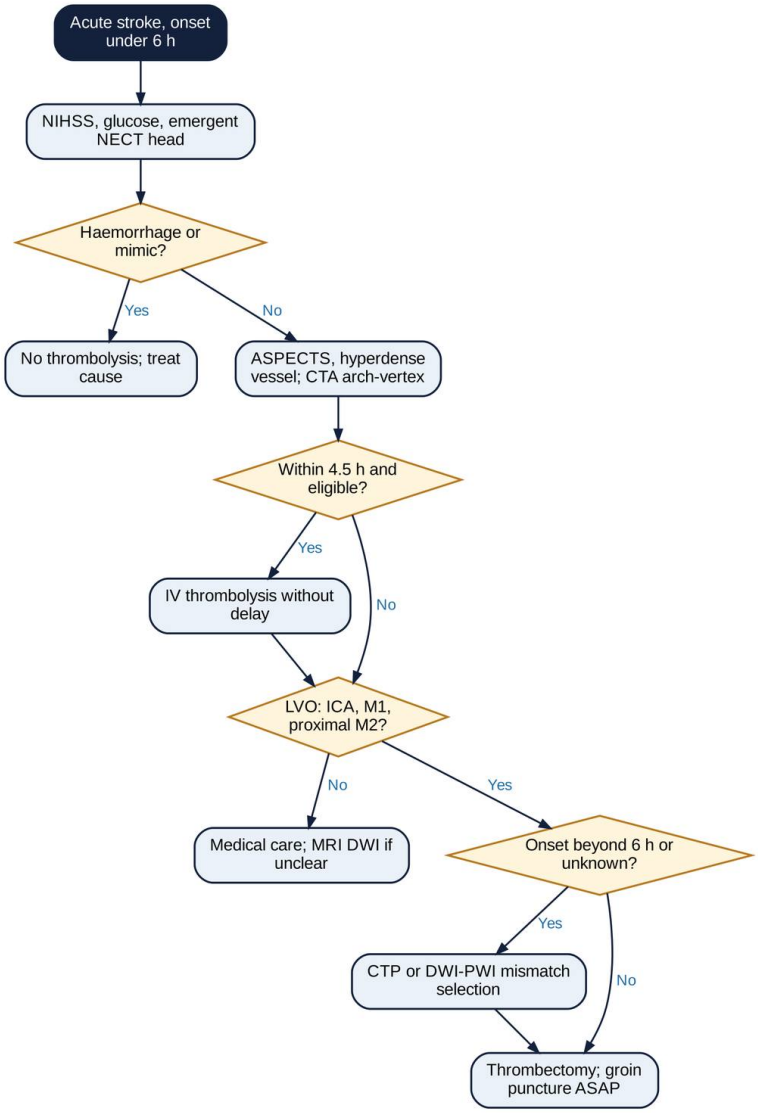

- Algorithm reasoning:
  - Haemorrhage on NECT means no thrombolysis.
  - If NECT is normal or shows hyperacute infarct, proceed to CTA head and neck to find the occlusion.
  - Within 4.5 h, IV thrombolysis is given if there are no contraindications.
  - Perfusion imaging is added outside the 6-hour window or in wake-up stroke.
- Current thrombolysis (AHA/ASA 2026): tenecteplase 0.25 mg/kg (max 25 mg) or alteplase 0.9 mg/kg is COR 1 within 4.5 h. Eligible patients with disabling deficits are treated without advanced imaging selection.
- A 30-year-old patient: look for dissection and other causes on CTA of the neck.

Role of interventional radiology

- **Mechanical thrombectomy** gives sustained benefit over standard care in anterior-circulation LVO (MR CLEAN, HERMES).
- It recanalises better than IV r-tPA in distal ICA and proximal MCA occlusion.
- Devices are stent retrievers or aspiration catheters, with IV thrombolysis where appropriate.

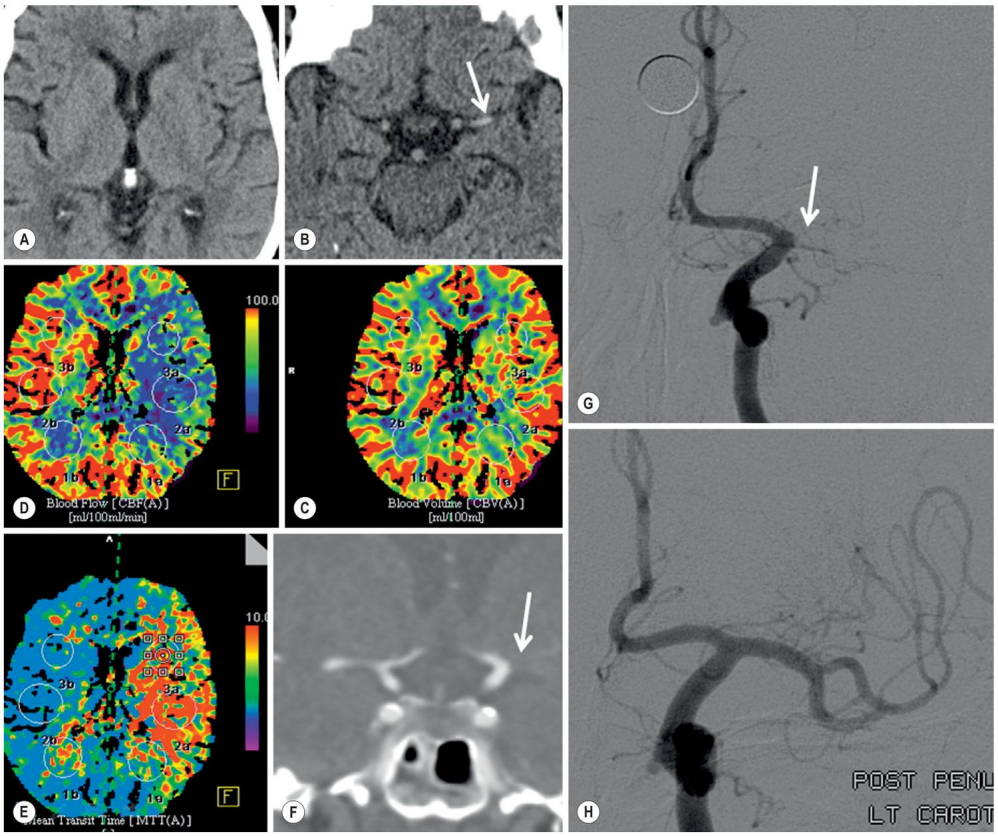

Fig. 56.12 — GA V2, p. 1451. Mechanical Thrombectomy to Recanalise an Occluded Left Middle Cerebral Artery Following Identification of a Large Penumbra Using Computed Tomography Perfusion. Within 90 minutes of the onset of severe right hemiparesis and receptive aphasia, the plain computed tomography (CT) showed a hyperdense left M1 segment (B, white arrow) but no parenchymal changes (A). There is also no e

- **Indications (UK guidance)**: NIHSS >5, occlusion of the intracranial ICA or proximal MCA, pre-stroke mRS <3, and arterial puncture within 6 h.
- **Current indications (AHA/ASA 2026)**:
  - 0–6 h: ICA/M1 LVO, NIHSS ≥6, pre-stroke mRS 0–1, ASPECTS 3 to 10 (COR 1).
  - ASPECTS 0–2 within 6 h: EVT is reasonable in selected patients.
  - Basilar occlusion: strong recommendation with NIHSS ≥10, posterior-circulation ASPECTS ≥6 and mRS 0–1.
- **Late window**: benefit up to 24 h with core/penumbra selection (DAWN, DEFUSE-3).
  - DAWN: 90-day functional independence 49% vs 13%.
  - 6–24 h large core: age <80 years, NIHSS ≥6, mRS 0–1, ASPECTS 3–5, no significant mass effect (COR 1).

Table 2: Thrombectomy and thrombolysis criteria, book versus current

Book (AMP, 3rd ed.)	Current (AHA/ASA, 2026)
ASPECTS ≥6, NIHSS ≥6, mRS 0–1, groin puncture within 6 h	ASPECTS 3 to 10 within 6 h, NIHSS ≥6, mRS 0–1
6–24 h: DAWN and DEFUSE-3 mismatch selection	6–24 h selected by ASPECTS, with CTP/MRI as adjunct (COR 2a)
Alteplase 0.9 mg/kg, max 90 mg	Tenecteplase 0.25 mg/kg or alteplase 0.9 mg/kg

Technique

1. Access via a 6-F/8-F sheath, then an initial angiogram to localise the occlusion.
2. Heparin 5,000 U bolus, then 1,000 U/h for 2 h or until the procedure ends.
3. A guide catheter is placed in the ICA. A microcatheter is advanced over a 0.14 microwire across the occlusion.
4. The **stent retriever** is deployed in the thrombus and left for a few minutes. Stent and clot are withdrawn with aspiration through the guide catheter.
5. Alternatively, a large-bore aspiration (Penumbra) catheter digests the clot with suction.

- **Complications**: sICH, SAH, IVH, vessel dissection, non-target emboli, vasospasm and stent dislocation.
- Intra-arterial fibrinolysis (PROACT) was the earlier option. It increased early ICH (27.8% vs 5.5% in PROACT 2).

PEARLS

- Earliest CT sign is the hyperdense artery. The earliest MRI sign is DWI hyperintensity with ADC hypointensity (from about 5 min).
- ASPECTS starts at 10 with 10 regions. A score below 7 means infarct over one-third of the MCA territory.
- Penumbra is Tmax >6 s. Mismatch is penumbra at least 20% larger than the core.
- NECT first, then CTA arch-to-vertex. CTP or DWI-PWI for late or unknown onset.
- Do not delay IV thrombolysis for advanced imaging within 4.5 h.
- Exam trap: do not quote the 2018 criteria (ASPECTS ≥6) as current. AHA/ASA 2026 allows ASPECTS 3–10 within 6 h.

260. Subarachnoid haemorrhage — causes, subarachnoid spaces, imaging evaluation and endovascular treatment of aneurysm

ASKED 3× · 10-mark answer

Asked in: Jun 2022 · Paper I · Q5 (10 marks) · Oct 2023 · Paper I · Q2 (10 marks) · Dec 2025 · Paper I · Q9 (10 marks)

Q: What are the causes of subarachnoid haemorrhage? Describe their imaging features in brief. [4+6]

Q: Describe the anatomy of the subarachnoid spaces. How will you investigate a case suspected of acute subarachnoid hemorrhage. Describe in brief endovascular management of intra-cranial aneurysm. [2+4+4]

Q: a) Enumerate the common causes of subarachnoid haemorrhage (SAH). [4] b) How will you evaluate a suspected case of SAH? [6]

SOURCE

GA V2 — Ch 56 Neurovascular Diseases — §Subarachnoid Haemorrhage, Aneurysmal SAH, Incidental Aneurysms, CVT, Haemorrhage summary — pp. 1465–1472, 1478
GA V2 — Ch 53 Current Status of Imaging of the Brain — §DSA, CTA, CTP — pp. 1381–1383
GA V2 — Ch 54 Imaging of Head Trauma — §Traumatic Subarachnoid Haemorrhage — p. 1403
GA V2 — Ch 58 Inflammatory and Metabolic Disease — §Secondary CNS vasculitis (RCVS) — p. 1521
AMP V4 — Ch 189 Imaging of Subarachnoid Hemorrhage — §SAH of Unknown Etiology — e.7494
[W1] AHA/ASA — 2023 Guideline for the Management of Patients With Aneurysmal Subarachnoid Hemorrhage (Hoh et al., Stroke 2023;54:e314–e370) — 2023 — https://www.ahajournals.org/doi/10.1161/STR.0000000000000436

Causes of subarachnoid haemorrhage

- **Aneurysm (about 80%)** is the commonest cause.
- **Non-aneurysmal perimesencephalic SAH (about 10%)**:
  - Blood is confined to the perimesencephalic basal cisterns.
  - By definition, catheter angiography is negative.

- **Traumatic SAH**, from blunt or penetrating injury, venous or arterial.
- **Rare causes**:
  - Arteriovenous malformation (AVM).
  - Dural venous sinus or cortical vein thrombosis.
  - Intracranial dissection.
  - Cocaine abuse.
  - Pseudoaneurysms.
  - Mycotic aneurysms.
  - Reversible cerebral vasoconstriction syndrome (RCVS).
- **SAH of unknown cause** forms 7–10% of cases. Reasons include:
  - An incomplete angiogram (PICA-origin aneurysm missed).
  - The lesion obliterated by the haemorrhage.
  - An aneurysm or AVM too small to see.
  - A cervical or upper thoracic AVM.

Imaging features of each cause

Table 1: Causes of SAH and their imaging features

Cause	Imaging features
Saccular aneurysm	Blood in the basal cisterns, often with intraventricular blood. Large aneurysms are rounded and enhance; giant aneurysms (>25 mm) have laminated thrombus and wall calcification; on spin-echo MRI a patent sac is a flow void.
Site clues (aneurysm)	**ACom:** septal clot extending into the frontal lobe. **MCA:** Sylvian blood ± temporal clot. **PCom:** isolated third nerve palsy. **Basilar tip:** interpeduncular fossa, brainstem or thalamic blood. **PICA:** fourth ventricle and craniocervical junction blood.
Perimesencephalic SAH	Small interpeduncular or perimesencephalic bleed. Good prognosis; rebleed risk is no higher than the general population.
Traumatic	Small SAH at the vertex gyri, Sylvian fissures, interpeduncular fossa or ambient cistern. Usually lower volume than aneurysmal SAH. Other injury (EDH, SDH, parenchymal) points to trauma.
Cerebral venous thrombosis	SAH is often seen. Cord-like hyperdense cortical vein (**string sign**); filling defect on CT venography; absent MRV flow; SWI blooming.
Mycotic aneurysm	Peripheral, on MCA branches; extensive white-matter oedema; peripheral intraparenchymal clot, in septicaemia or endocarditis.
RCVS	Sulcal SAH with multifocal segmental narrowing on angiography, which normalises at follow-up (3 months).
AVM / dural fistula	Small pial or dural fistulae need DSA when CTA is negative.

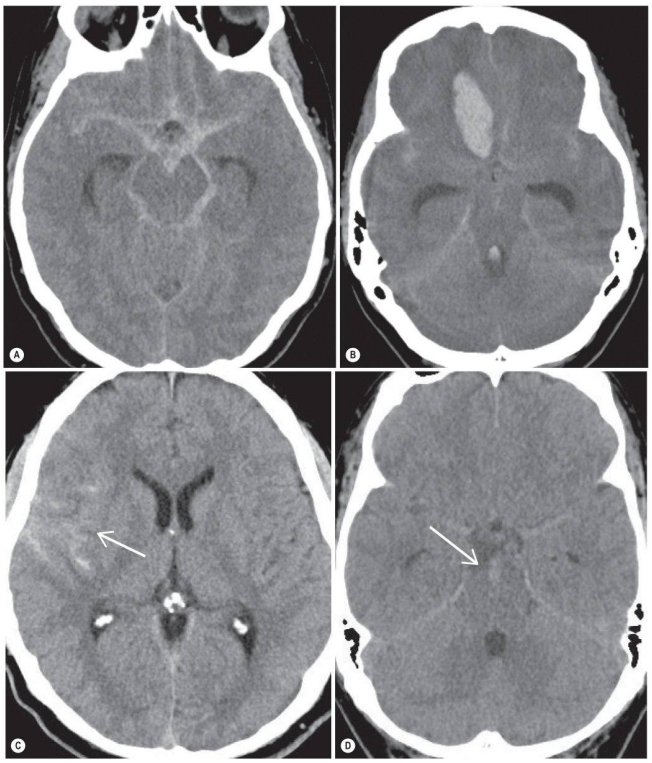

Fig. 56.30 *— GA V2, p. 1468. Distributions of Acute Subarachnoid Haemorrhage. (A) Diffuse subarachnoid haemorrhage (SAH) within basal cisterns. (B) SAH with a focal parenchymal haematoma in the right inferior temporal lobe. This is very suggestive of an anterior communicating complex aneurysm—note the temporal horn dilatation in keeping with hydrocephalus. (C) SAH in the right Sylvian fissure suggests a mi*

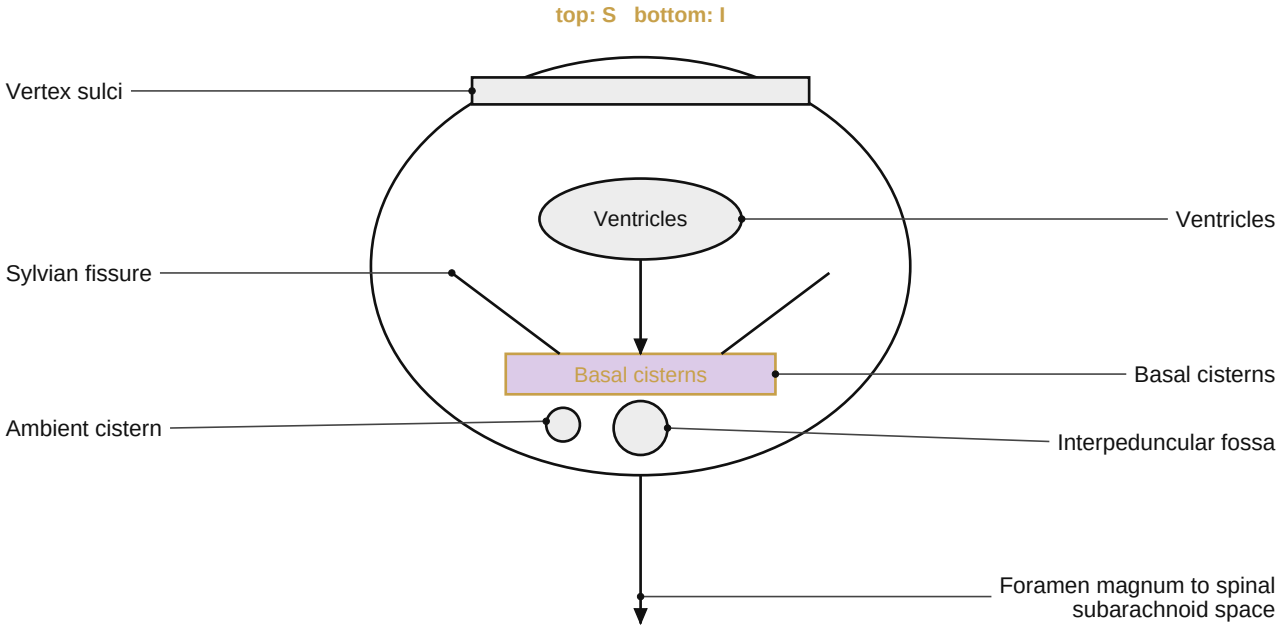

Schematic (exam diagram): Subarachnoid spaces: sites to inspect for SAH (midline schematic). *Based on GA V2 pr.1403, pr.1467, pr.1470, pr.1471.*

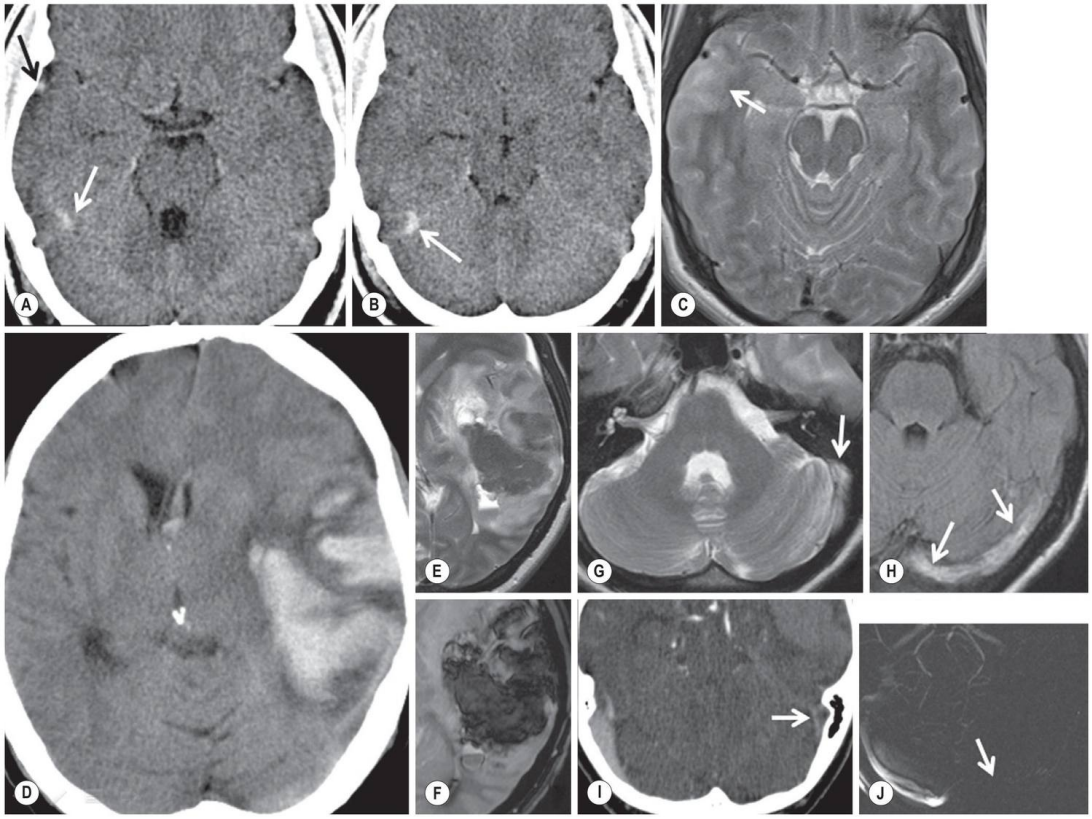

Fig. 56.28 *— GA V2, p. 1466. Cerebral Venous Thrombosis. (A–C) This young male patient presented with headache and seizures. Serpiginous hyperdensity on computed tomography (CT) within a vessel on the surface of the right temporal lobe (A, black arrow) and approaching the right lateral venous sinus (A and B, white arrows) is consistent with the 'string sign' of cortical venous thrombosis—in this case, invo*

Anatomy of the subarachnoid spaces

- CSF-containing space lies over the cerebral gyri and fills the sulci, fissures and basal cisterns. SAH conforms to this space.
- **Sites to inspect for blood**:
  - Gyri at the vertex.
  - Sylvian fissures.
  - Interpeduncular fossa.
  - Ambient cistern (focal blood here may indicate a brainstem contusion against the tentorium).
- **Basal cisterns** lie around the circle of Willis, where most aneurysms arise, so aneurysmal blood collects here.
- The space communicates freely with the ventricles. Intraventricular blood can diffuse into it, and the reverse.
- It continues through the foramen magnum into the spinal subarachnoid space.
- CSF pulsation artefact in the basal cisterns and at the foramen magnum can mimic abnormal FLAIR signal.

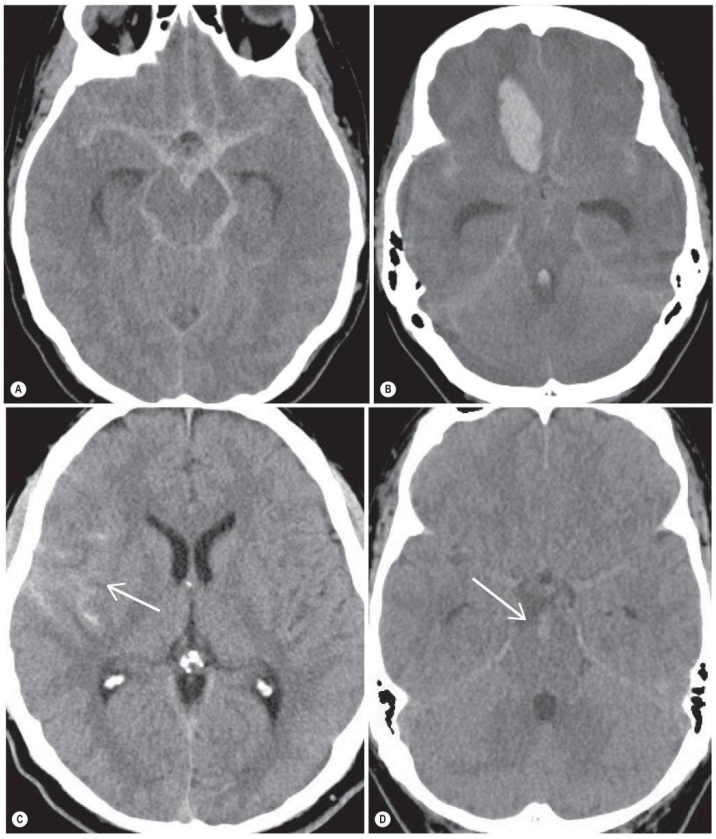

Fig. 56.30 — GA V2, p. 1468. Distributions of Acute Subarachnoid Haemorrhage. (A) Diffuse subarachnoid haemorrhage (SAH) within basal cisterns. (B) SAH with a focal parenchymal haematoma in the right inferior temporal lobe. This is very suggestive of an anterior communicating complex aneurysm—note the temporal horn dilatation in keeping with hydrocephalus. (C) SAH in the right Sylvian fissure suggests a mi

Investigation and evaluation of suspected acute SAH

Stepwise imaging

- **Non-contrast CT head first:**
  - Acute blood is hyperdense in the CSF spaces.
  - Review the vertex, Sylvian fissures and interpeduncular fossa carefully.
  - Look for hydrocephalus. Mild temporal horn dilatation is a clue when blood is not obvious.
- **Lumbar puncture** when CT is negative but suspicion is strong:
  - Do it at least 6 h, ideally 12 h, after ictus.
  - This allows red cell lysis, so bilirubin can be detected.
- **MRI** when CT is negative or the presentation is late:
  - Spin-echo is unreliable. **T2* GRE or FLAIR** sensitivity is 94–100% when acute (<4 days) and 81–87% when subacute (>4 days).
  - FLAIR may stay positive up to 45 days.
  - Sulcal FLAIR hyperintensity is non-specific. Causes include supplemental oxygen, leptomeningeal engorgement, post-infarct contrast leakage and CSF pulsation artefact.
  - Chronic repeated SAH shows **superficial siderosis** on T2*/SWI.
- **CT angiography:**
  - It is the standard initial investigation for SAH in the acute setting.
  - The whole head is imaged in under 10 seconds.
  - Review source images and MPRs; take care near the skull base.
  - Do it early, as rebleed risk is highest in the first 48 h.
  - Typical combined neck and intracranial CTA protocol: 50–70 mL contrast at 4–5 mL/s, then a saline chaser.
- **DSA** (gold standard):
  - Use it for a negative CTA, unclear anatomy or small vascular malformations.

  - Repeat the study if vasospasm marred a negative angiogram.
  - 3D rotational angiography has a complication rate of about 0.5–2%.
  - If the first angiogram is negative, repeat it after about 6 weeks.
- **MRA (3D TOF)** is preferred in the non-acute setting, for screening and for follow-up.
- **Subacute complications**:
  - Communicating hydrocephalus.
  - Vasospasm, usually 4–11 days after the bleed. CT perfusion can detect it.

Table 2: Timing and thresholds in SAH imaging

Book (GA 7e)	Current (AHA/ASA 2023)
CT is positive in 98% within 12 h, falling to under 75% by day 3.	Within 6 h of onset with no new deficit, CT on a high-quality scanner read by a neuroradiologist is reasonable to exclude aSAH; sensitivity 98.7%.
LP if CT is negative, at least 6 h and ideally 12 h after ictus.	Severe headache more than 6 h from onset, or with a new deficit: CT, then LP if CT is negative.
CTA sensitivity for aneurysm is above 90%; small aneurysms at the skull base are hard to resolve.	CTA sensitivity is about 97.2%, but only 61% for ruptured aneurysms under 3 mm.
DSA confirms a negative CTA in most centres.	DSA is indicated for a negative or inconclusive CTA when an aneurysm is likely, and for diffuse SAH regardless of CTA.

Flowchart 1: Evaluation of suspected acute SAH

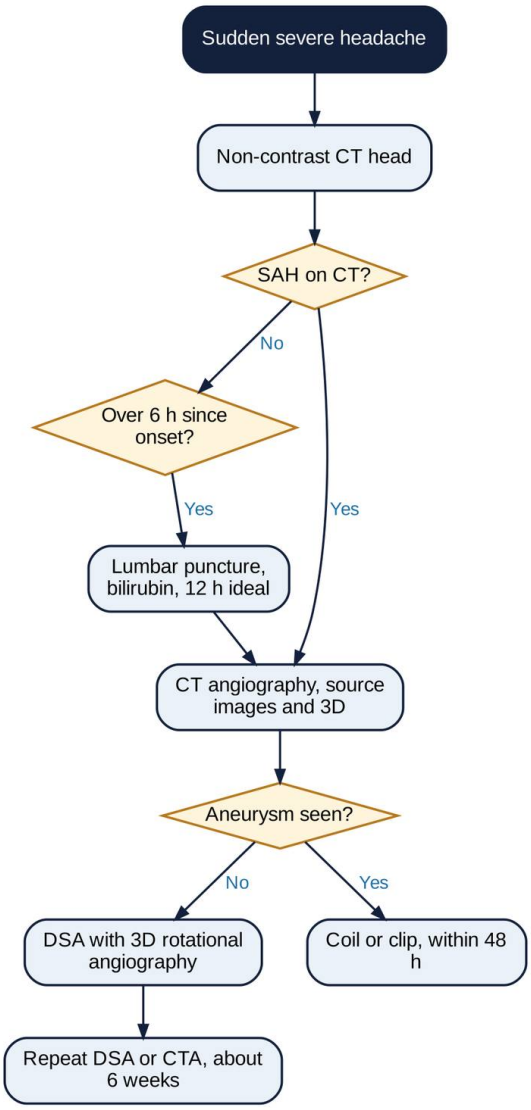

Endovascular management of intracranial aneurysm

- **Indications:** ruptured aneurysm, treated early. Endovascular treatment is recommended as soon as possible, within 48 h of ictus.
- **Choice of treatment:**
  - For good-grade anterior circulation aneurysms where coiling and clipping are both feasible, primary coiling is recommended (class I, level A).
  - For posterior circulation aneurysms, coiling is preferred over clipping when feasible.
  - In the multicentre randomised comparison, death or dependency at 1 year was 23.5% with coiling versus 30.9% with clipping.
  - At 7 years, coiling had a lower risk of epilepsy but more rebleeding.
- **Technique:**

1. Femoral (or radial) access by the Seldinger technique, usually under local anaesthesia.
2. Microcatheter placed in the aneurysm sac.
3. Detachable platinum coils, with or without gel coating, are deployed.
4. Balloon-assisted or stent-assisted coiling prevents coil prolapse into the parent vessel.
5. Wide-neck aneurysms may need an intrasaccular **WEB** device or flow diversion.

- **Related endovascular procedures:**
  - Intra-arterial vasodilator therapy or angioplasty for vasospasm.
  - Flat-detector CT in the angiography suite can detect haemorrhagic complications without transfer.
- **Follow-up:** CTA or MRA. DSA is needed for suspected complications or metallic implants.
- **Risks:** diagnostic cerebral angiography carries 0.3–1.5% risk, and endovascular treatment more. Specific risks:
  - Thromboembolism and stroke.
  - Arterial spasm, thrombosis and dissection from the catheter or wire.
  - Coil compaction with refilling (seen in a wide-neck MCA aneurysm).

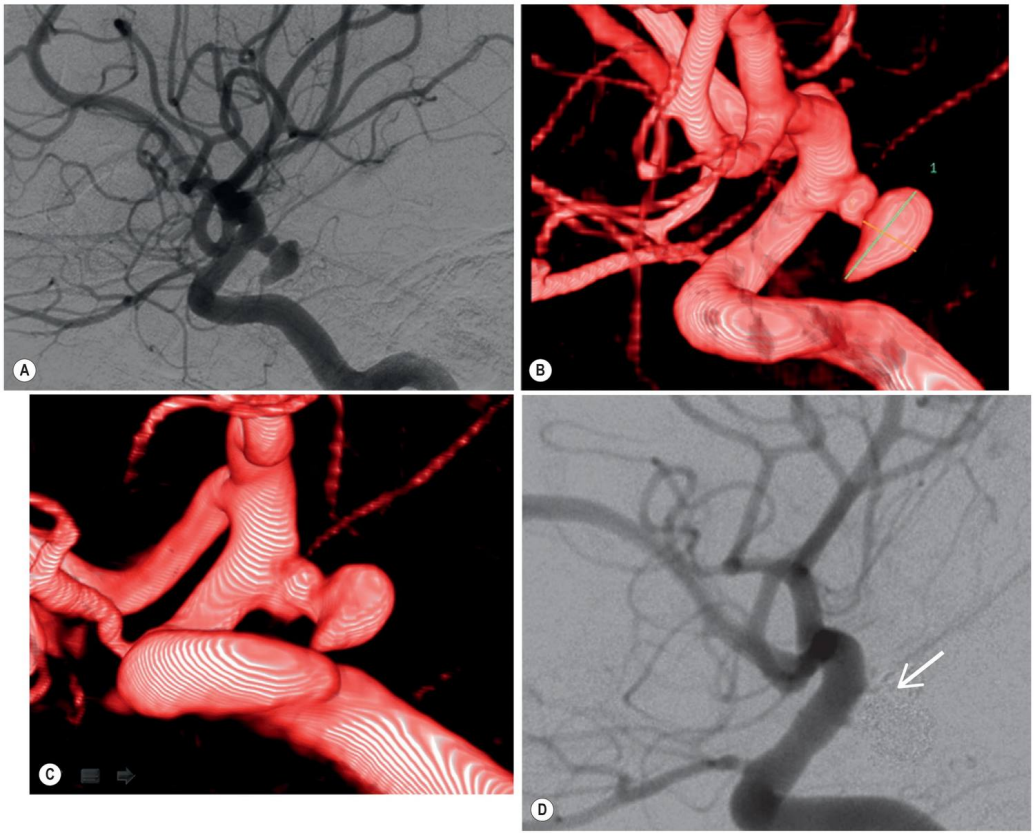

Fig. 56.31 *— GA V2, p. 1470. A 37-Year-Old Female Patient Presents With an Acute-Onset Painful Right Third Nerve Palsy With Pupil Involvement. Computed tomography angiography demonstrated the presence of a lobulated posterior communicating artery (Pcomm) aneurysm. (A) The Pcomm aneurysm is demonstrated at digital subtraction angiography (DSA). (B and C) The size and position of the aneurysm neck is further*

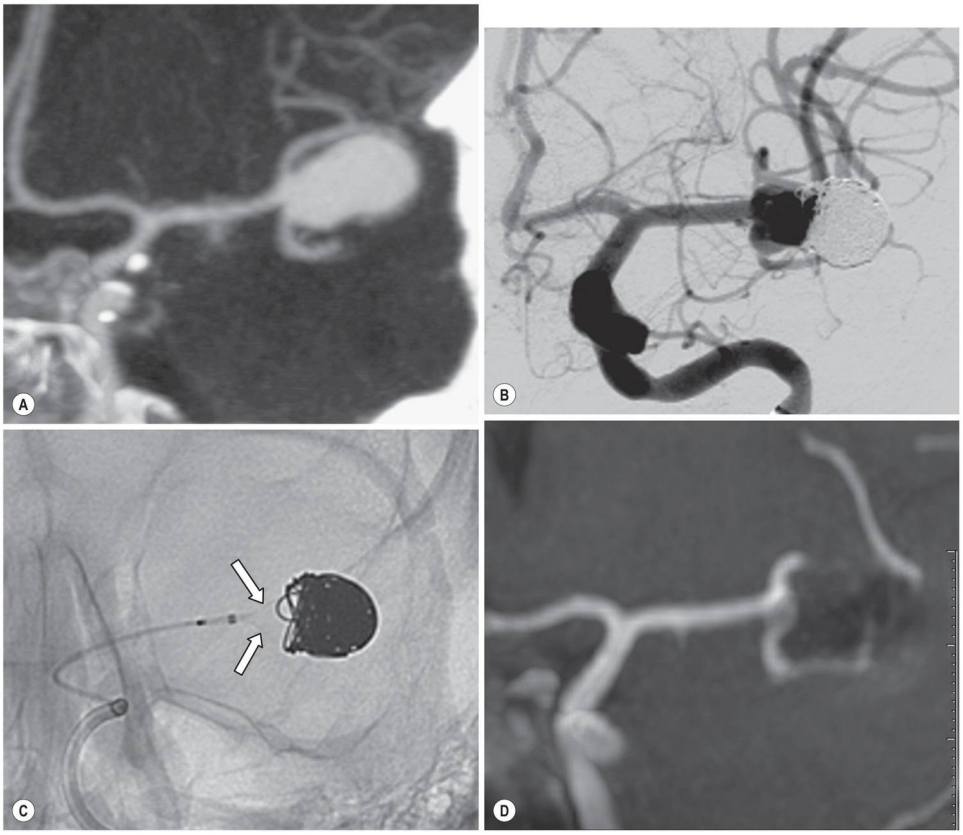

Fig. 53.40 *— GA V2, p. 1383. Patient With Ruptured Left Middle Cerebral Arteries Aneurysm. (A) Computed tomography angiography shows wide-neck aneurysm. (B) Initially, it is treated by coiling. Loose packing at the aneurysm neck led to compaction and refilling of the aneurysm. (C) Re-treatment with intrasaccular flow diverter (WEB device) (arrows). (D) A 6-month follow-up magnetic resonance angiography sho*

PEARLS

- SAH is mostly aneurysmal (about 80%). Perimesencephalic non-aneurysmal SAH (about 10%) has a good prognosis.
- NCCT is the first test. CT is about 98% sensitive within 12 h, falling below 75% by day 3.
- If CT is negative, LP at 6–12 h or MRI (FLAIR/T2* GRE).
- CTA is the standard first angiographic test. Negative CTA with SAH needs DSA.
- Blood distribution points to the aneurysm: septal clot means ACom; Sylvian blood means MCA; interpeduncular blood means basilar tip or perimesencephalic SAH.
- Vasospasm peaks at 4–11 days. Rebleed risk is highest in the first 48 h, so secure the aneurysm early.
- Trap: sulcal FLAIR hyperintensity is not specific for SAH.

261. Intracranial aneurysms — sites, aetiology and the role of interventional radiology

ASKED 1× · 10-mark answer

Asked in: Oct 2024 · Paper I · Q8 (10 marks)

Q: Discuss the common sites and etiologies of intracranial aneurysms. What is the role of interventional radiology in their management? [4+6]

SOURCE

GA V2 — Ch 56 Neurovascular Diseases — §Initial Investigation of Acute SAH; Aneurysmal SAH; Imaging of Incidental Intracranial Aneurysms — pp. 1467–1472
AMP V4 — Ch 189 Imaging of Subarachnoid Hemorrhage — §Unruptured Aneurysms — e.7479
AMP V4 — Ch 190 Endovascular Management of Intracranial Aneurysms — e.7500, e.7501, e.7509, e.7510
AMP V4 — Ch 209 Endovascular Management of Craniofacial Vascular Lesions — §Aneurysms — e.8502
[W1] AHA/ASA — 2023 Guideline for the Management of Patients With Aneurysmal Subarachnoid Hemorrhage (Hoh et al., Stroke 2023;54:e314–e370) — 2023 — https://www.ahajournals.org/doi/10.1161/STR.0000000000000436

Common sites and aetiology of intracranial aneurysms

Sites

- Aneurysms are most often **saccular**. They are round or lobulated and arise at arterial bifurcations, mainly around the circle of Willis.
- About 90% arise from the carotid (anterior) circulation. The other 10% arise from the vertebral or basilar arteries.
- About 20% are multiple.
  - 75% of multiple aneurysms are double. There is a strong female predominance.
  - Aneurysms may be bilateral and symmetrical (**mirror aneurysms**).
- **Giant aneurysms** measure over 25 mm and make up about 5% of aneurysms. They often contain layered organised thrombus.

Table 1: Common sites of intracranial aneurysms and the bleed pattern that localises them

Site	Frequency	Localising clue
Anterior communicating artery (Acom)	About one-third	Clot in septum pellucidum, extending into frontal lobe, is virtually diagnostic
Posterior communicating artery (Pcomm)	About one-third	Isolated painful third nerve palsy from pulsatile pressure
Middle cerebral artery (MCA) bifurcation	About 20%	Sylvian fissure bleed, sometimes temporal clot
Basilar termination	About 5%	Blood in interpeduncular fossa, brainstem or thalami; poor prognosis
Posterior inferior cerebellar artery (PICA) origin	About 5%	Intraventricular blood via fourth ventricle; clot at craniocervical junction and spinal subarachnoid space;
Distal anterior cerebral artery (pericallosal)	Less common	Rarer site

- A ruptured aneurysm causes subarachnoid haemorrhage (SAH). Aneurysm accounts for 80% of SAH.
- In multiple aneurysms, the ruptured one is identified by the following.
  - Contrast extravasation (pathognomonic).
  - Adjacent clot or mass effect, and local SAH or vasospasm.
  - A proximal location, the largest size or an irregular shape.

Aetiology and types

- **Saccular (berry) aneurysm** is the commonest type. It is a true aneurysm with all arterial wall layers.
  - Haemodynamic stress at bifurcations drives wall degeneration. The amplification of flow and wall shear stress matters more than hypertension alone.
- **Fusiform** aneurysm is an extreme form of focal ectasia in hypertensive arteriosclerotic disease.
  - Atherosclerotic aneurysms are elongated with no defined neck. The vertebrobasilar system is the commonest site.
- **Dissecting** aneurysm follows a tear through the intima and internal elastic lamina.
  - Acute ones usually present with haemorrhage. Chronic ones usually compress adjacent structures.
- **Infective (mycotic)** aneurysm is caused by septic emboli, usually from endocarditis.
  - It is peripheral, typically on MCA branches.
  - It usually presents with a peripheral intraparenchymal clot and extensive surrounding white matter oedema.
  - It accounts for 2–4% of aneurysms. The commonest organisms are *Streptococcus viridans* (bacterial) and *Aspergillus fumigatus* (fungal).
- **Traumatic** pseudoaneurysm accounts for under 1% of aneurysms but 5–15% in children. The pericallosal artery is the commonest site.
- Associated conditions (acquired and genetic):
  - Autosomal dominant polycystic kidney disease (ADPKD), Ehlers–Danlos syndrome, Marfan syndrome, fibromuscular dysplasia and neurofibromatosis.
  - Pseudoxanthoma elasticum, hereditary haemorrhagic telangiectasia, coarctation of the aorta and α1-antitrypsin deficiency.
  - SLE, Takayasu arteritis and giant cell arteritis.

- Family history matters. With two first-degree relatives affected, up to 17% of family members harbour an unruptured aneurysm.
- Exogenous risk factors are smoking, cocaine and heavy alcohol use.

Role of interventional radiology

Diagnosis and planning

- **DSA** is the gold standard for aneurysms. Its high spatial and temporal resolution shows the smallest aneurysms and allows treatment planning.
- **3D rotational angiography** resolves aneurysms hidden by overlying vessels and shows the relation of the aneurysm to adjacent vessels. It is invasive, with a 0.5–2% complication rate.
- **CTA** is the standard initial investigation in acute SAH.
  - It images the whole head in under 10 seconds and is very sensitive for aneurysms of 3 mm and over.
  - It should be done early, because re-bleeding is greatest in the first 48 hours.
- DSA is still needed to confirm a negative CTA in most centres, when anatomy is unclear, and for small vascular malformations.
- If a negative angiogram is marred by vasospasm, repeat it.
- Guideline: DSA is indicated when SAH is spontaneous, an aneurysm is strongly suspected and CTA is negative or inconclusive. For diffuse SAH, DSA is indicated regardless of CTA.

Flowchart 1: Imaging and treatment pathway in suspected aneurysmal SAH

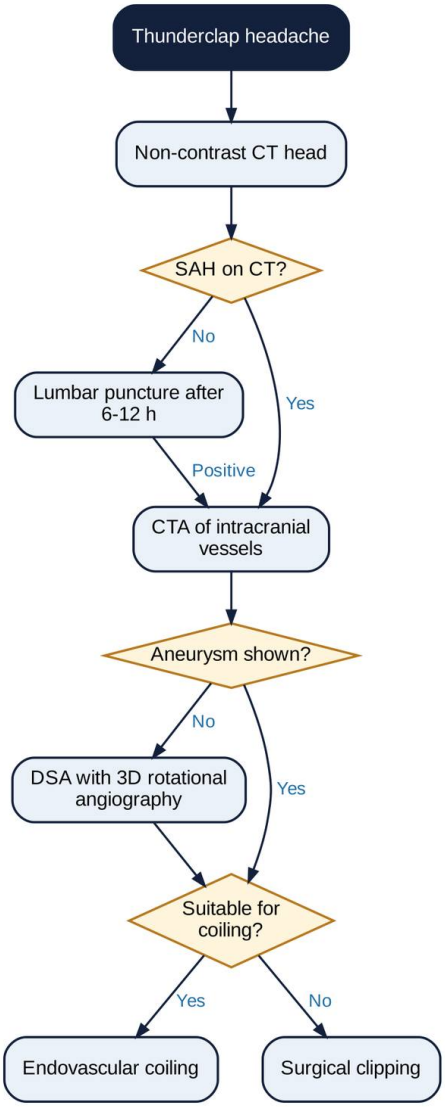

Endovascular treatment of the ruptured aneurysm

- Treatment is by surgical clipping or endovascular coiling. Detachable platinum coils (with or without a gel coating) are delivered through a microcatheter placed in the sac.
- Coiling can be assisted by a catheter-mounted balloon or a stent across the neck, to stop the coil ball prolapsing into the parent vessel.
- A multicentre randomised trial showed better 1-year outcomes for coiling than clipping. Death or dependency was 23.5% vs 30.9% (absolute risk reduction 7.4%).
  - The benefit persisted at 7 years, with less epilepsy but more re-bleeding in the coiled group.
- AHA/ASA 2023: early repair prevents re-bleeding.
  - For good-grade anterior circulation aneurysms where both options are viable, primary coiling is endorsed (class I, level A).
  - For posterior circulation aneurysms, coiling is recommended over clipping when feasible.

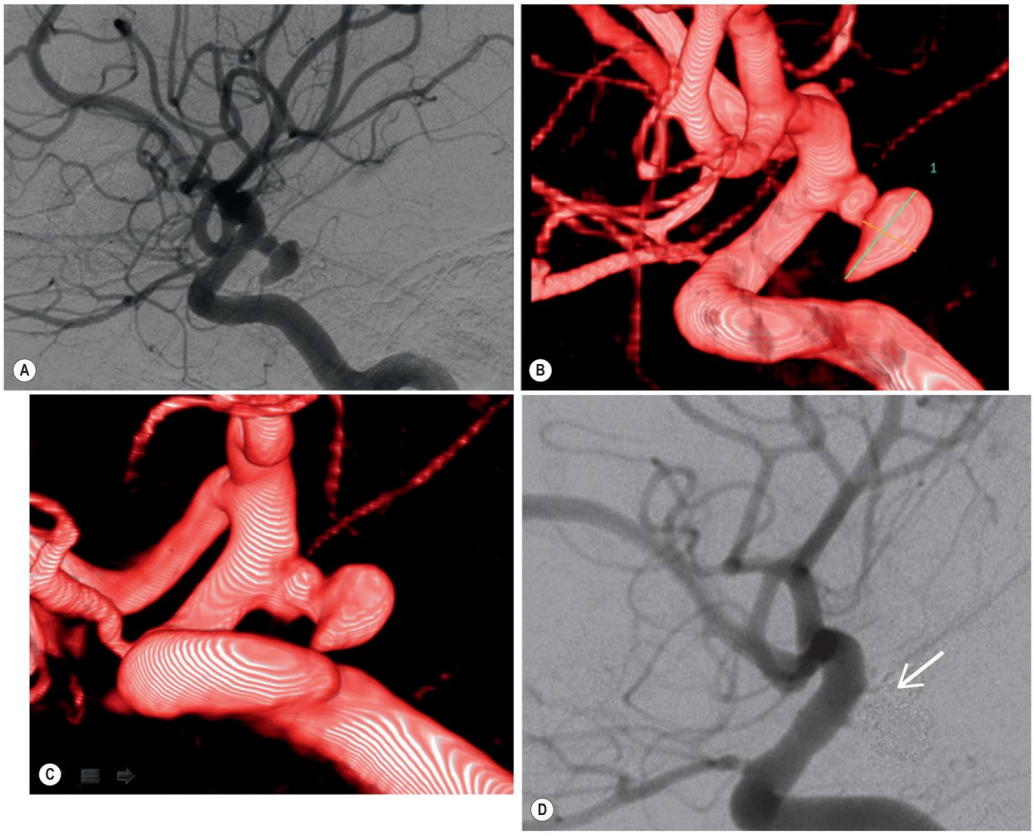

Fig. 56.31 *— GA V2, p. 1470. A 37-Year-Old Female Patient Presents With an Acute-Onset Painful Right Third Nerve Palsy With Pupil Involvement. Computed tomography angiography demonstrated the presence of a lobulated posterior communicating artery (Pcomm) aneurysm. (A) The Pcomm aneurysm is demonstrated at digital subtraction angiography (DSA). (B and C) The size and position of the aneurysm neck is further*

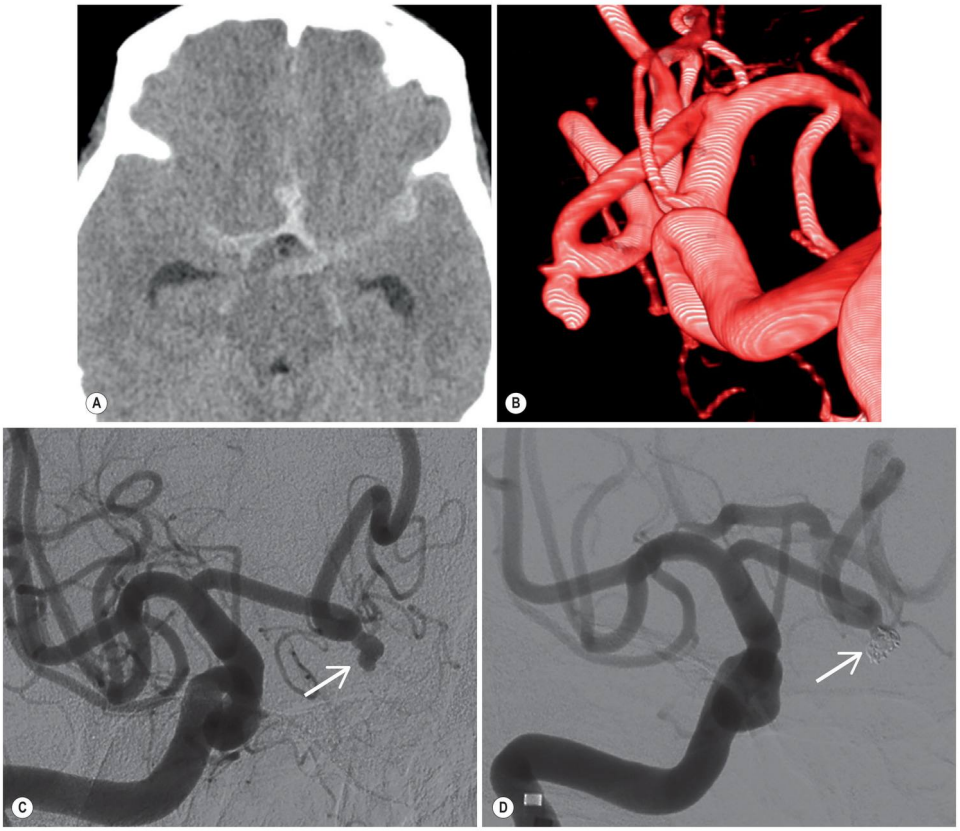

Fig. 56.32 — GA V2, p. 1472. A 50-Year-Old Presents With an Acute-Onset Headache. (A) Non-enhanced cardiac computed tomography demonstrates acute subarachnoid blood. (B and C) Three-dimensional digital subtraction angiography characterises the lobulated anterior communicating artery aneurysm prior to endovascular coiling where it is completely excluded from the circulation (D).

Table 2: Endovascular techniques for intracranial aneurysms

Technique	Indication	Key points
Simple coiling	Narrow-neck saccular aneurysm	A 3D framing coil forms a basket. Helical filling coils follow until the sac stops opacifying.
Balloon-assisted coiling	Wide neck (dome:neck ratio under 2)	A non-detachable balloon is inflated across the neck during coiling. It is deflated to test coil stability before detachment. Avoids a stent and antiplatelets.;
Stent-assisted coiling	Wide-necked or dysplastic aneurysms not suitable for simple or balloon-assisted coiling	The stent acts as a scaffold and reduces inflow. Self-expanding laser-cut or braided stents are used. Variants include jailing the microcatheter and the stent-jack technique.
Parent artery occlusion	Fusiform or wide-necked aneurysms, and fragile fresh traumatic pseudoaneurysms (extradural carotid/vertebral lesions)	Detachable balloons or coils are used. Preserve the ophthalmic artery (with ICA aneurysms) and PICA (with vertebral aneurysms).

Procedure

1. Femoral access. Catheterise the aneurysm with a microcatheter and microwire under roadmap.
2. Deploy the framing coil, then filling coils, until a dense coil mass forms and the sac no longer opacifies.
3. Withdraw the microcatheter slowly. Do a check angiogram for the degree of occlusion, parent artery patency and distal vasculature.
4. Remove the sheath. Apply manual compression for 30–40 minutes (or use a closure device). Transfer to neuro-ICU and keep the leg immobile for at least 6 hours.

Unruptured and incidental aneurysms

- There is no benefit from treating anterior circulation aneurysms of 7 mm or less with no prior SAH (ISUIA). Larger or posterior circulation aneurysms (including Pcomm) favour intervention, depending on size and life expectancy.
- MRA is preferred in the non-acute setting. Uses are screening, follow-up of incidental aneurysms and follow-up of coiled aneurysms. 3D TOF MRA is the most accepted technique.

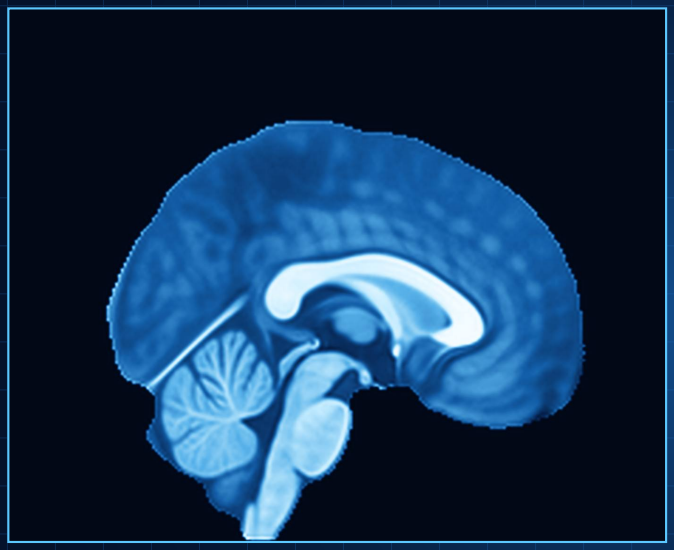

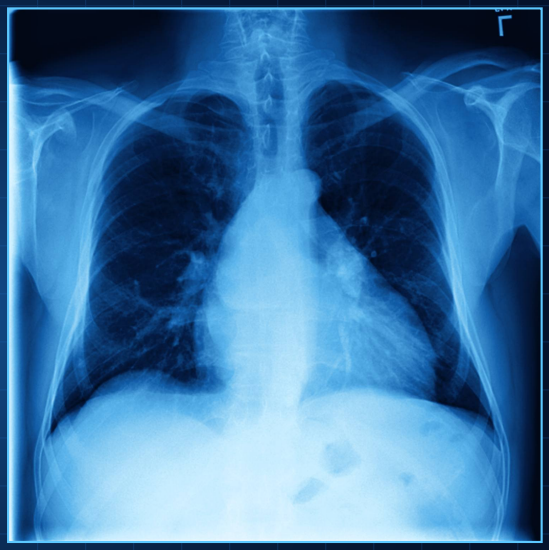

DNB RADIODIAGNOSIS · EXIT EXAM SERIES

Every question. Every paper. One answer.

This series solves the DNB Radiodiagnosis theory papers question by question. Every version of a question that has been asked across sessions is grouped together, and one complete answer is written to cover all of them, with a frequency badge that shows how often it appears. Each answer names the textbook chapter and pages it is drawn from, carries labelled figures and a quick exam diagram that can be reproduced in two to three minutes, and brings in current reporting systems, guidelines and Indian regulations.

THE COMPLETE SERIES

VOL 1 | VOL 2 | VOL 3 | VOL 4

REVIEWED BY

Dr Hemant Kumar · Dr. Khusbo Singh

DNB Radiodiagnosis

CLINICA

PUBLICATION

Cover images: MNI ICBM152 2009a T1 MRI template (McConnell Brain Imaging Centre, MNI) · Chest radiograph: NIH Clinical Center ChestX-ray dataset

Visit www.clinicapublication.com to order